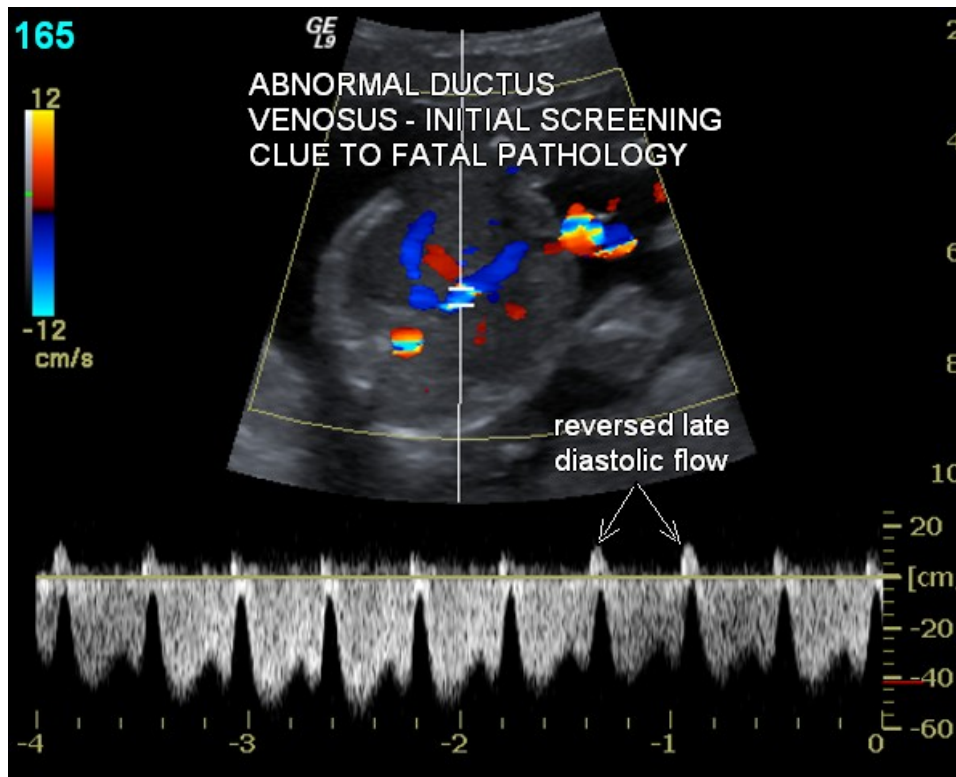


**CASE STUDY: CARDIOVASCULAR GENETIC/LEVEL II ULTRASOUND
DIAGNOSIS OF DUCTUS VENOSUS TO HEPATIC ARTERIAL FISTULA –
FETAL DEATH FOUR WEEKS LATER**

HISTORY: 43-year-old patient who declined screening and karyotyping was referred for a Cardiovascular Genetic/Level II Obstetrical Ultrasound.

Ultrasound identified a single umbilical artery, no structural heart disease, and was otherwise unremarkable with the exception of an abnormal ductus venosus waveform pattern – reversal of flow during late diastole – *Image 1*. All other noncardiac and cardiovascular Down syndrome markers were negative including normal course to the right subclavian artery.

Image 1



The presence of an abnormal ductus venosus waveform demanded my hands-on scanning. A fistula between the ductus venosus and the right hepatic artery was diagnosed - *Image 2*. *Image 3* demonstrates abnormal high volume low resistive hepatic arterial flow resulting from the shunting of blood from the ductus venosus.

Image 2

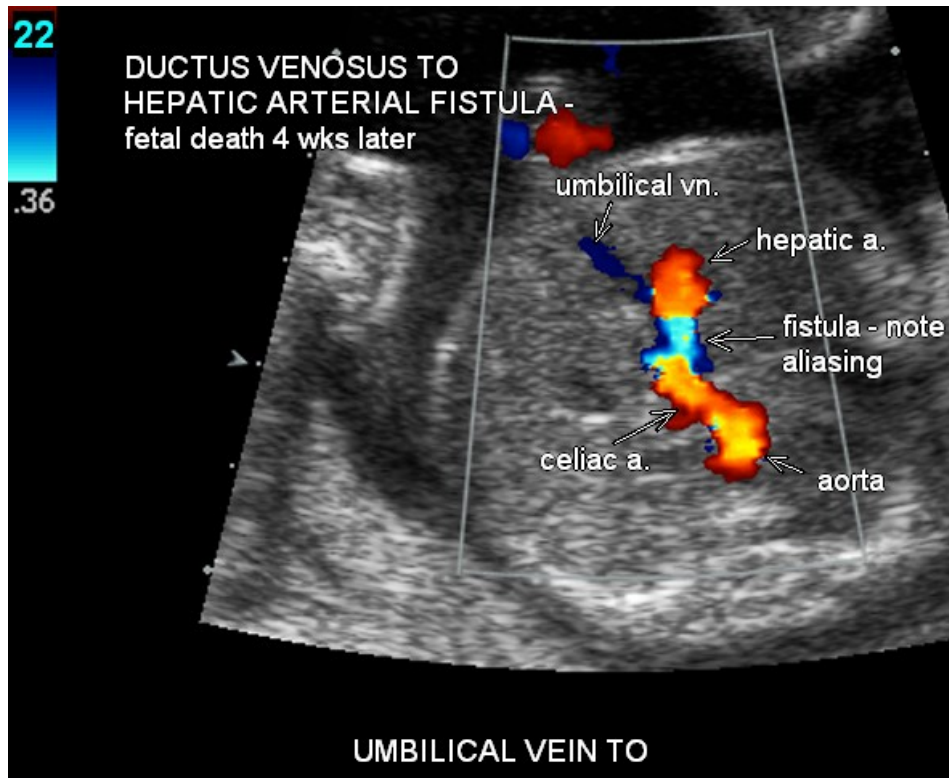
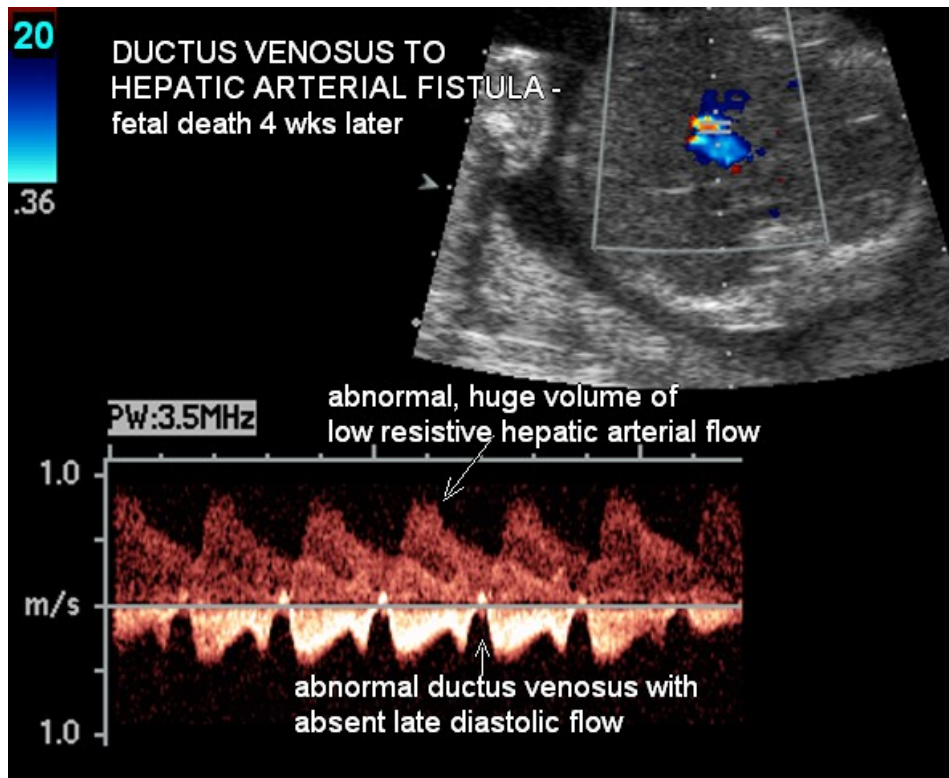


Image 3



I counseled the patient regarding the clinical implications of the ductus venosus-hepatic arterial fistula, that being additional increased risk for Down syndrome and the significant risk for fetal death or poor outcome. This malformation exemplifies one of several vascular anomalies found with statistically significant increased incidence in the Down syndrome population. The Cardiovascular Genetic/Level II Ultrasound Exam detects such anomalies. These anomalies include – aberrant pattern of umbilical venous drainage, agenesis of the ductus venosus, and aortic arch and brachiocephalic arterial anomalies including aortic coarctation, right aortic arch, aberrant right and aberrant left subclavian arteries and vascular rings.

The two pathophysiologic pathways for poor outcome are the shunting of blood away from the intestines resulting in intestinal ischemia and metabolic acidosis and/or high output cardiac failure.

This is the third such case that I have seen within the last year, two of which resulted in fetal death and the other resulted in severe growth restriction, preterm delivery, with neonatal death.

The patient declined karyotyping. Second opinion MFM and pediatric cardiology consultative reports made no mention of this frequently fatal pathology. Second opinion consultants provided the patient with no additional information regarding prognosis.

Intrauterine fetal death occurred four weeks after my initial exam.

SUMMARY: The maternal-fetal imaging division of Hudson Valley Radiology has thirty years of experience in the detection, diagnosis, and imaging management of fetal cardiovascular pathology. This fund of knowledge forms the basis upon which we have implemented a Universal Fetal Cardiovascular Genetic/Level II Obstetrical Ultrasound program.

The cardiovascular ultrasound exam is an evidence-based, pregnancy outcome verified study that achieves the following goals:

- 90% Down syndrome risk sensitivity which increases to 98% following normal first and/or second trimester screening.
- Optimizes detection and diagnosis of management-altering cardiac malformations, venous and arterial anomalies.
- Optimizes fetal and neonatal well-being.
- Minimizes medical-legal exposure.



Prenatal Diagnosis of Intrahepatic Arterial-Venous Fistula Associated with Down syndrome. Ultrasound Obstetrics and Gynecol. 2000; Vol. 15. Hartung.

Abnormalities of the Umbilical-Portovenous System in Down syndrome. Am J Med. Gen; 120. 528-532. Pipitone.

Congenital Intrahepatic Portosystemic Venous Shunts in Infant with Down Syndrome. Am J Roentgenology; 2004; 183: 1783-1784. Saxena.

Aberrant Right Subclavian Artery: A Marker for Chromosomal Abnormality. Ultrasound Obstet and Gynecol. 2010; 36:548-552. Borenstein.

The Umbilical Vein Anomaly in Fetuses with Down syndrome. Ultrasound Obstetrics and Gynecol. 2010; 297-301. Achiron

Prenatal Diagnosis of Ductus Venosus Agenesis and its Association with Cytogenetics/Congenital Anomalies. Prenatal Diagnosis. 202; 995-1000.