



# Universal Fetal Cardiac Ultrasound – At the Heart of Newborn Well-being

**Optimizes detection of congenital heart disease (chd) in the general low risk obstetrical population**

Daniel J. Cohen, M.D.



[danjcohen@optonline.net](mailto:danjcohen@optonline.net)

914-391-0109

# Universal fetal cardiac ultrasound and the Cardio Vascular Genetic/Level 2 Obstetrical Ultrasound Exam

Optimizes detection of CHD and in doing so optimizes risk assessment for chromosomal & non chromosomal syndromes.

**From the patients perspective – why do we perform antenatal ultrasound?**

Is my baby (fetus) okay?

Are there malformations that might hurt my baby in utero or after birth or alter where and how I deliver?

Unbeknownst to most parents and many health care providers is the 2-3% incidence of congenital malformations in the general low risk populations (2 – 3 fetal malformations per 100 deliveries.)

-Congenital malformations represent the overwhelming majority of morbidity & mortality in the new born period.

-Congenital heart disease is the most common of these malformations.

## UNIVERSAL FETAL CARDIAC ULTRASOUND

The community standard that defines our imaging protocol is influenced by our proximity to tertiary care centers performing neonatal cardiac surgery. Antenatal detection of congenital heart disease with non-emergent delivery at such centers has proven to improve neonatal outcome.

Our protocols, therefore, must detect pathologies whose treatment will effect outcome and exclude those pathologies that would preclude delivery at a community hospital setting.

## UNIVERSAL FETAL CARDIAC ULTRASOUND

Current imaging guidelines (American Institute of Ultrasound in Medicine) for cardiac assessment during the 18-22 week detailed anatomic exam (CPT 76811) and genetic/Level II obstetrical ultrasound only require four chamber cardiac view of the heart and suggest (but not necessitate) an “attempt” at outflow tract assessment “when technically feasible”. Screening with four chambers views of the heart only detect 25-50% cardiac malformations and will miss the great majority of potentially cyanotic lesions such as tetralogy of Fallot, transposition, double outlet right ventricle, truncus arteriosus.

Journal of Ultrasound in Medicine 2005, p. 1752. Letter to Editor.

American Institute of Ultrasound in Medicine. AIUM Practice Guidelines for the Performance of an Antepartum Obstetrical Ultrasound Examination. Laurel: American Institute of Ultrasound in Medicine; 2003.

Available as: <http://www.AIUM.org/publication/clinical/obstetrical.PDF>

## UNIVERSAL FETAL CARDIAC ULTRASOUND

- CHD is the most common and most serious of all structural malformations. 1/200 - 1/300 fetuses have heart malformations that necessitate delivery at a university hospital setting.
- The profound majority of fetuses with CHD are born to couples with no history nor risk factor.

Benacerraf. Accuracy of Fetal Echocardiography. Radiology 1987; 165: 847-849

Mitchell. Congenital Heart Disease in 56, 109 Births: Incidence of Natural History. Circulation 1971; 34:323-332.

## UNIVERSAL FETAL CARDIAC ULTRASOUND

- CHD is the most frequently missed malformation at the time of “routine” detailed 18- week ultrasound.
- CHD is the number one cause for significant morbidity and mortality in the first year of life. 10% of newborns who die in the first year of life do so with an undiagnosed heart defect.

Yagel. Congenital Heart Defects: Natural Course and In Utero Development. Circulation 1997;96:550-555.



## FAST FACTS ON FETAL CONGENITAL HEART DISEASE (CHD)

- CHD is the malformation most responsible for infant morbidity and mortality accounting for greater than one-third of infant deaths related to congenital malformation.
- Without a prenatal diagnosis, even severe forms of congenital heart disease commonly go undetected until after discharge to home leading to avoidable morbidity and mortality.
- 20-55% of infants with CHD are not diagnosed until after hospital discharge. Most obstructive left heart lesions (such as aortic coarctation) are not diagnosed at birth or at six weeks.

## FAST FACTS ON FETAL CONGENITAL HEART DISEASE (CHD)

- Aortic coarctation is one of the three undiagnosed conditions (the others are hypoplastic left heart and interrupted arch) most likely to lead to death soon after discharge from hospital.
- During first year of life 25% of deaths due to CHD occur before the diagnosis of CHD.

## UNIVERSAL FETAL CARDIAC ULTRASOUND

- 15% of fetuses with CHD have abnormal chromosomes so if the heart defect is missed you miss the opportunity to karyotype.
- 50% of Down syndrome fetuses have CHD, Screening for Down Syndrome is therefore incomplete without a dedicated study of the heart.

Nyberg. Diagnostic Imaging of Fetal Abnormalities, 2003. P. 453.

Ferentz, C. Perspectives in Pediatric Cardiology. Vol 4. Congenital Heart Disease: The Baltimore-Washington Infant Study, 1981-9. New York: Putura Publishing, 1993.

## UNIVERSAL FETAL CARDIAC ULTRASOUND

Cardiac anomalies are the most overlooked lesions during prenatal ultrasound scanning and all the benefits of early prenatal diagnoses are withheld from the families if the cardiac diagnoses are missed.

Yagel. Congenital Heart Defects: Natural Course and In Utero Development. Circulation 1997;96:550-555.

## UNIVERSAL FETAL CARDIAC ULTRASOUND

Fetal cardiac ultrasound is necessary to **complete and optimize** detection of malformations that alter obstetrical management, site of delivery, aneuploidy risk assessment, neonatal well being and minimize emergency transfer of sick newborns.

## UNIVERSAL FETAL CARDIAC ULTRASOUND

### HVRA Outcome analysis - a ten year retrospective analysis of transfer rates of sick newborns

Outcome analysis - a ten year retrospective analysis of transfer rates of sick newborns with the ICD9 codes of congenital heart disease (CHD) delivered at Nyack Hospital demonstrates a transfer rate of 3-4 per 3,000 – significantly lower than the national average of 9-15 per 3,000 for similar sized hospital (biostatistics obtained from Center for Disease Control).

## UNIVERSAL FETAL CARDIAC ULTRASOUND

**How fetal cardiac ultrasound can help you take better care of your patients.**

Statistically significant reduction in transfer rate of sick newborns in comparison to national average. How? 4 – 5 fold increase in the detection rate of cardiac and noncardiac malformations at the time of the mid second trimester anatomy scan.

## UNIVERSAL FETAL CARDIAC ULTRASOUND

**How fetal cardiac ultrasound can help you take better care of your patients.**

Statistically significant reduction in transfer rate of sick newborns in comparison to national average.  
How? 4 – 5 fold increase in the detection rate of cardiac and noncardiac malformations at the time of the mid second trimester anatomy scan.



This significant diminution in transfer rates of sick newborns is achieved by performance of 2D fetal cardiac ultrasound and the early detection of CHD at the time of the mid second trimester anatomy scan.

## UNIVERSAL FETAL CARDIAC ULTRASOUND

We report for a fetal cardiac exam accompanying a detailed 18 – 22 week anatomy scan.

“ No signs of hypoplastic left heart, atrioventricular septal defect, tetralogy of fallot, transposition nor aortic coarctation- the most common clinically significant patterns of CHD detectable on antenatal ultrasound. “

# UNIVERSAL FETAL CARDIAC ULTRASOUND

The two accompanying articles from the December 2007 *Journal of Ultrasound In Medicine* substantiate HVRA's imaging philosophy that every pregnant woman should be offered a fetal cardiac ultrasound at the time of her detailed 18 – 22 week anatomy scan.

## Improving Detection of Fetal Cardiac Anomalies *A fetal echo cardiogram for every fetus?*

Bahtiyar and Copel. Pg 1639 - 1641.

## Prenatal Detection of Congenital Heart Disease in Southern, Nevada. The need for universal fetal cardiac evaluation.

Acherman. Pg. 1715 - 1719.

J. Ultrasound Med 26:2007.

# UNIVERSAL FETAL CARDIAC ULTRASOUND

The existing guideline for “outflow tract imaging when possible” promulgated by CPT and AIUM guidelines has had no effect in improving the national detection rate of congenital heart disease 15-30%.

- 4 chamber heart view detects only 40 – 50% of potentially cyanotic patterns of CHD

Prenatal Detection of Congenital Heart Disease in Southern Nevada  
The Need for Universal Fetal Cardiac Evaluation  
J. Ultrasound Med 26:1715-1719

## UNIVERSAL FETAL CARDIAC ULTRASOUND

It is not the mere performance of “outflow tract” imaging but the detailed knowledge of fetal cardiac pathology, its recognition, and the interpretative expertise that is necessary to substantially increase detection rate of CHD\*.

It is these special skills that define 2D fetal cardiac assessments. HVRA’s protocols and intervention identify CHD at rates concordant with the highest levels quoted in the literature (approximately 80%)

\* Prenatal Detection of Congenital Heart Disease in Southern Nevada  
The Need for Universal Fetal Cardiac Evaluation  
J. Ultrasound Med 26:1715-1719

# UNIVERSAL FETAL CARDIAC ULTRASOUND

## Pregnancy Outcome Quality Assurance Program and Data Base

- Every OB patient who has First Trimester Screening and/or detailed mid second trimester anatomy scan receives in the mail a pregnancy outcome questionnaire.

### 2008 Census

- 1642 questionnaires mailed out, 381 responses
- 23% response rate
- Amongst responders no clinically significant neonatal pathology found that was not seen on antenatal ultrasound

## 2008 HVRA CENSUS FOR FETAL CARDIOVASCULAR MALFORMATIONS

- Total number of detailed 76811 exams – 2,718
- Total number of 2D fetal cardiac exams – 2,275
- Total number of cardiovascular malformations - 22, including isolated right aortic arch and isolated agenesis of ductus venosus both with normal heart - 6

## 2008 HVRA Census for fetal malformations

### Fetal cardiovascular malformations – 22 cases:

- Transposition of the great vessels – 2
- Truncus arteriosus – 2
- Tricuspid atresia with pulmonary stenosis – 2
- Tetralogy of Fallot – 2
- Double outlet ventricle with coarctation – 1
- Aortic coarctation – 1
- Atrioventricular septal defect – 1
- Large atrial septal defect – 1
- 2:1 atrioventricular block – 1



## 2008 HVRA Census for fetal malformations

### Fetal cardiovascular malformations continued:

- Agenesis of the ductus venosus with aberrant course to the intraabdominal umbilical vein
  - In association with metabolic storage disorder – 1
  - Part of multi-malformative syndrome – 1
  - In association with large atrioseptal defect – 1
- Right aortic arch with no structural heart disease – 2
- Aberrant right subclavian artery with left aortic arch, normal variant – 2
- Aberrant right subclavian artery as part of Down syndrome with tetralogy of Fallot – 1
- Cardiac rhabdomyomas with tuberous sclerosis - 2

**MOST FREQUENTLY QUOTED INCIDENCE OF  
CLINICALLY SIGNIFICANT CONGENITAL HEART DISEASE AMONGST  
NEWBORNS – 1:200-1:300**

## **HVRA'S 2008 DETECTION RATE**

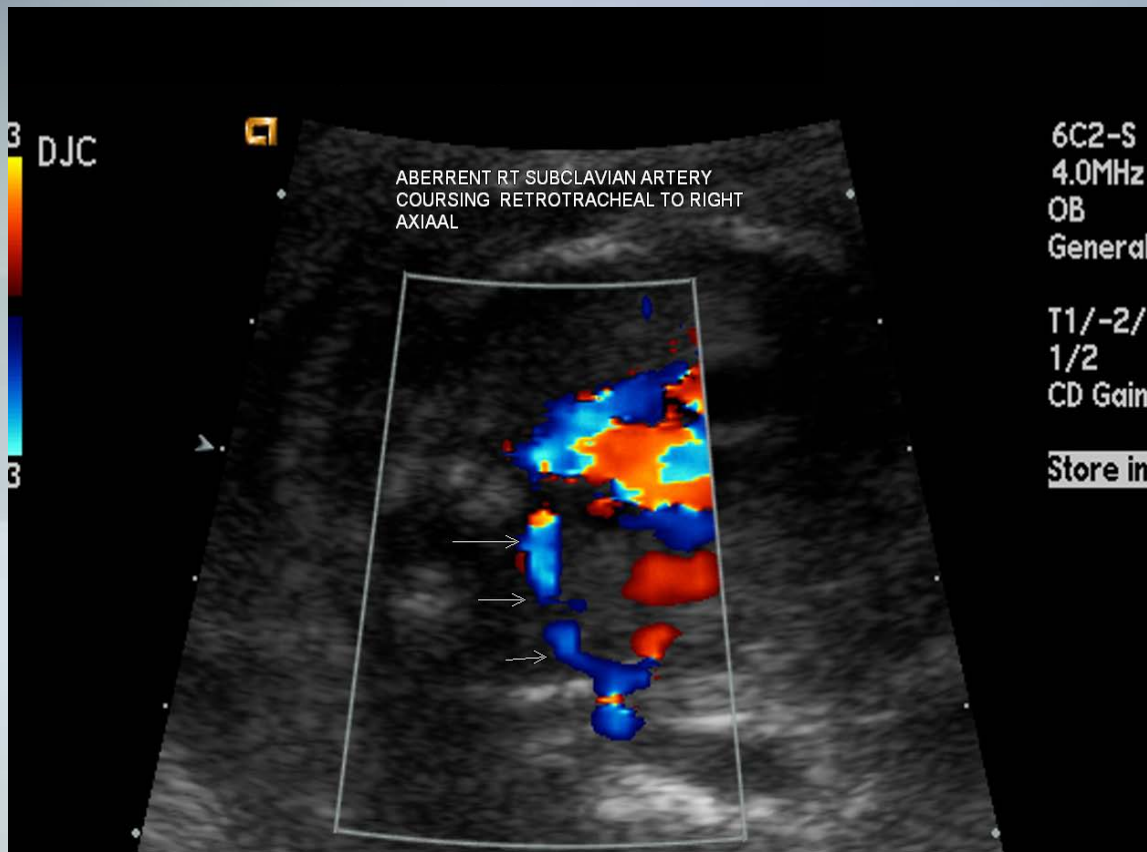
- All cardiovascular malformations –  
 $22/2,718 = 2.4$  cases per 300 newborns
- Not including isolated right aortic arch and isolated  
agenesis ductus venosus both with normal heart –  
 $16/2,718 = 1.8$  cases per 300 newborns.

**Cardiovascular Genetic/level II obstetrical ultrasound exam is an evidence-based pregnancy outcome verified program with a 90% Down syndrome detection rate which goes up to 98% after normal first or second trimester screening.**

A 90% risk reduction can be applied to patients first trimester and/or second trimester screening results.

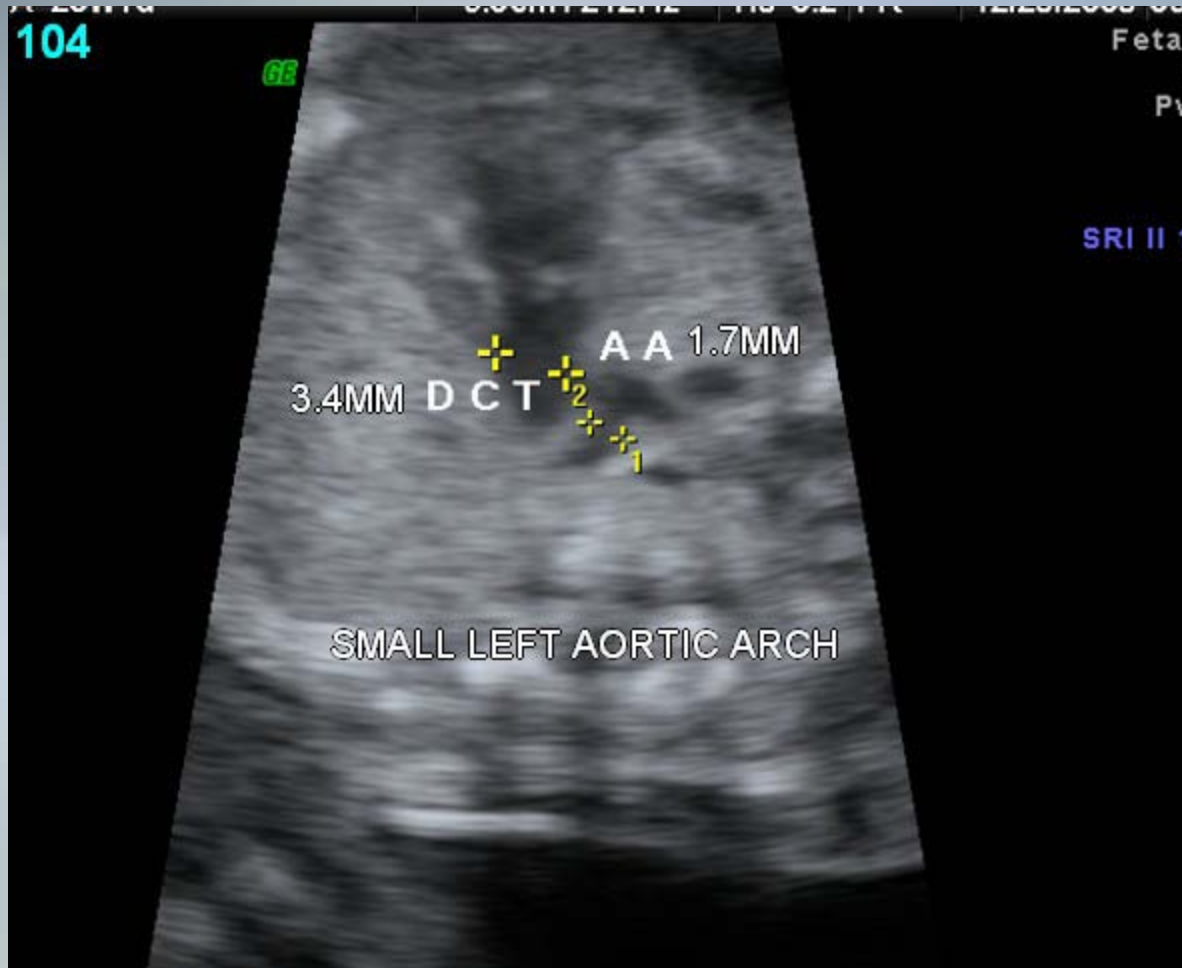Example – For a patient whose screening results indicate an elevated 1:200 Down syndrome risk but is ambivalent or refuses amniocentesis, a negative cardiovascular genetic ultrasound will risk reduce to 1:1818 based on 90% risk reduction.

**Aberrant right subclavian artery – Down syndrome marker.  
Likelihood ratio of 10**

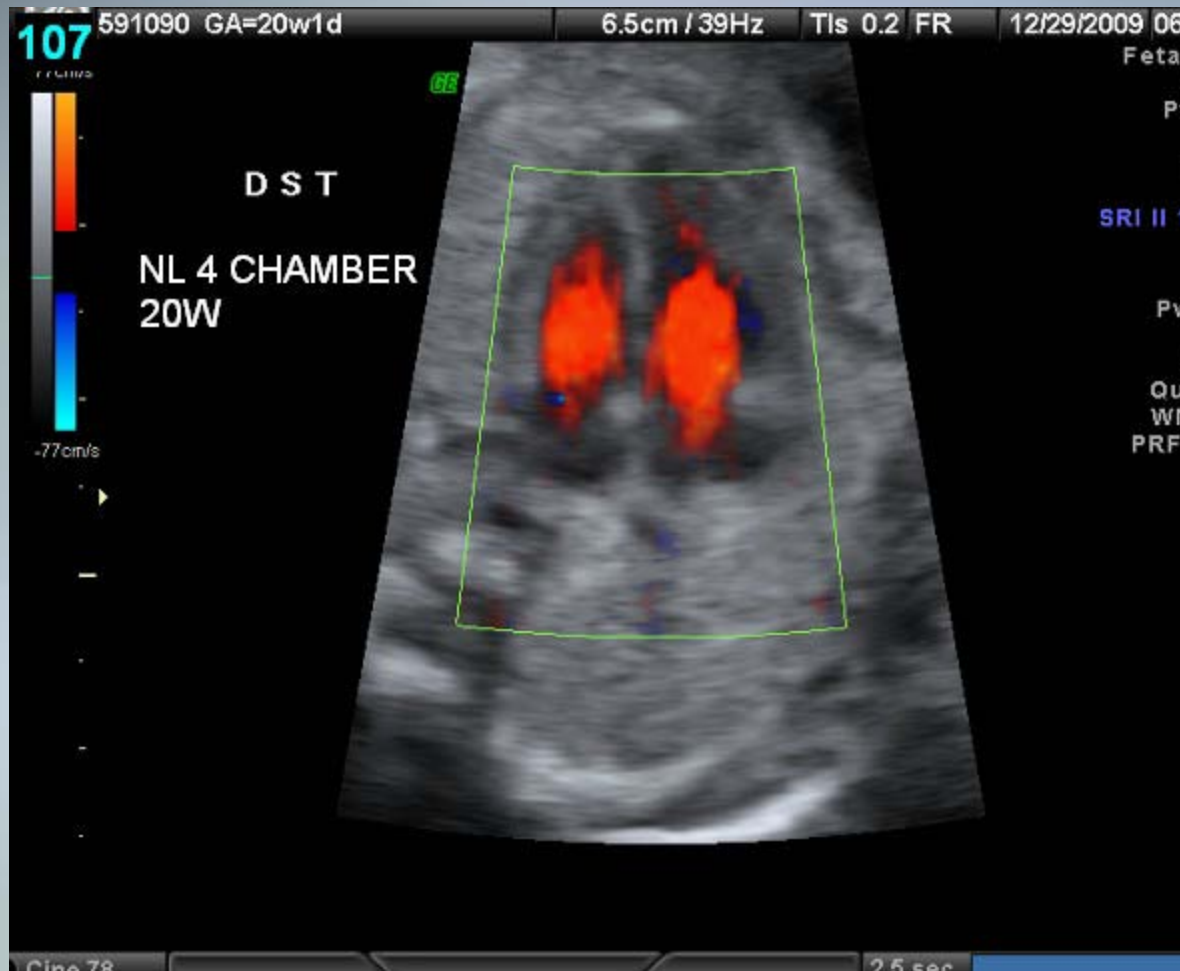

# Aortic coarctation – syndromic marker.

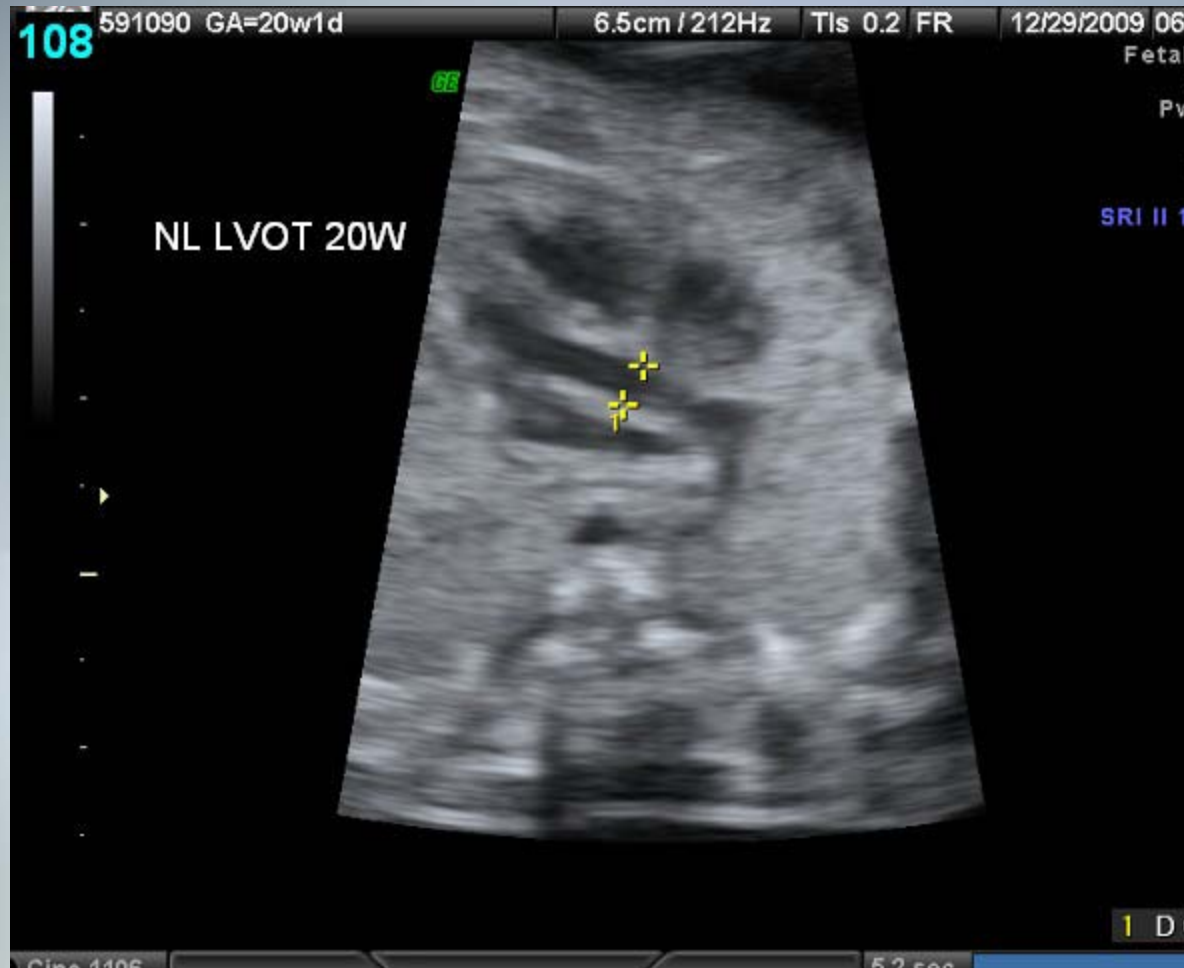Deliver at tertiary care center



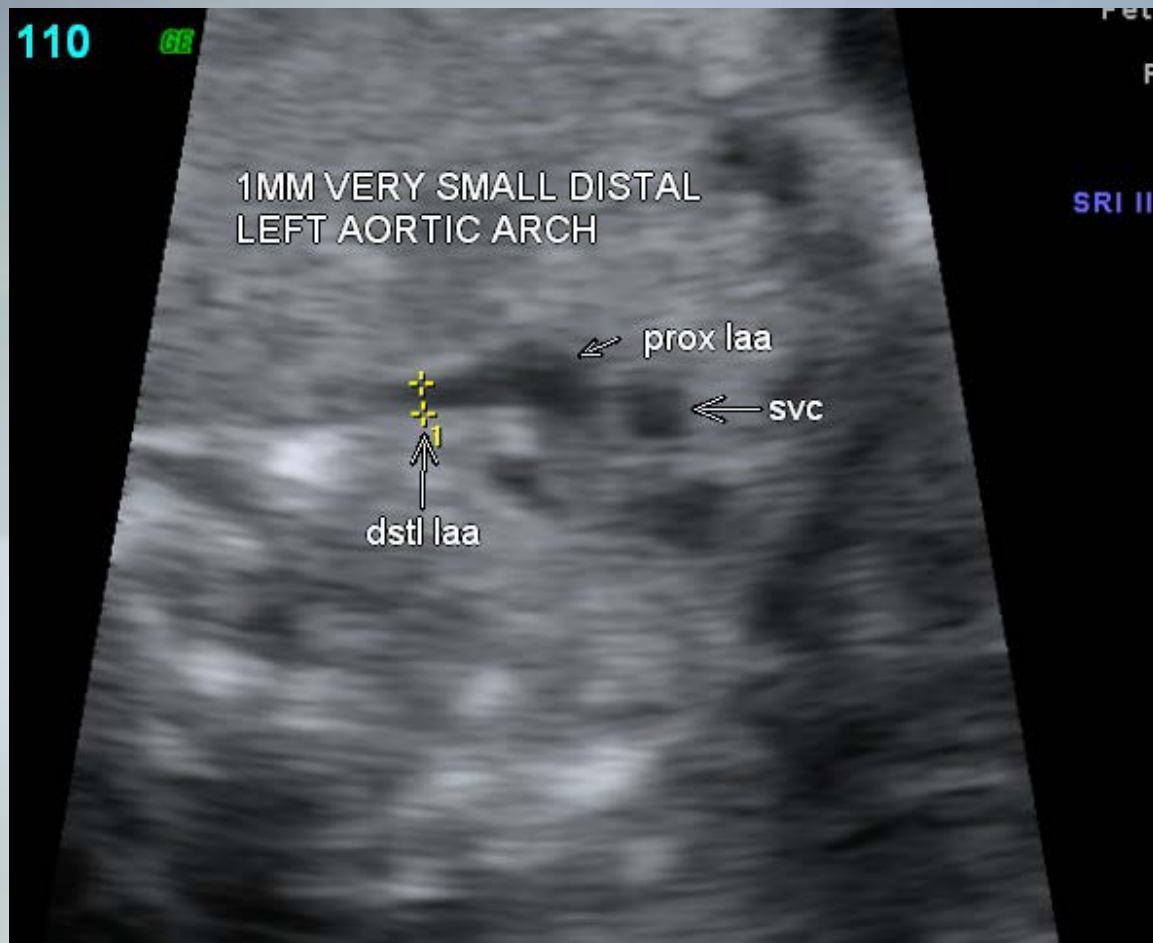# Normal four chamber heart in fetus with aortic coarctation



# Normal left ventricular outflow tract in fetus with aortic coarctation

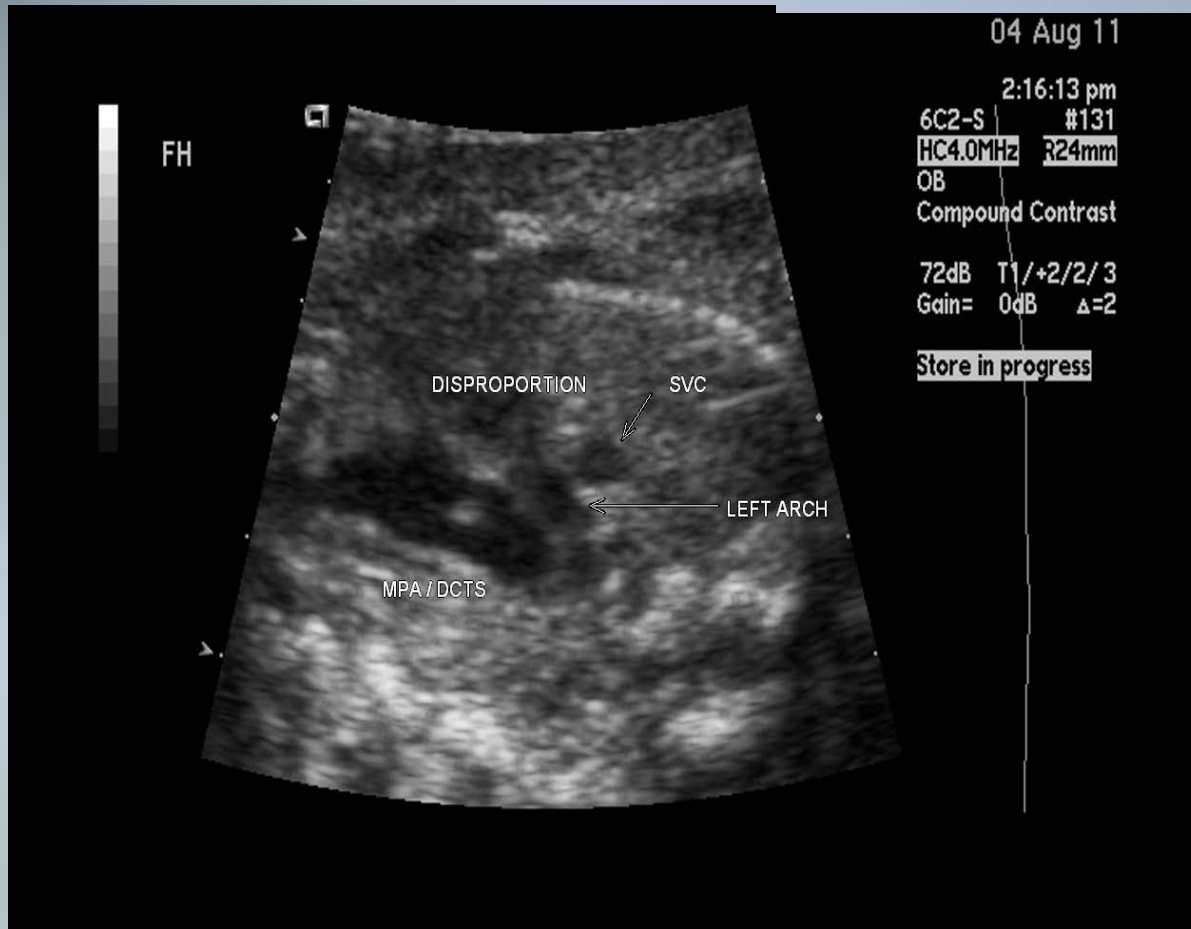

## Aortic coarctation – necessity of transverse imaging through upper chest

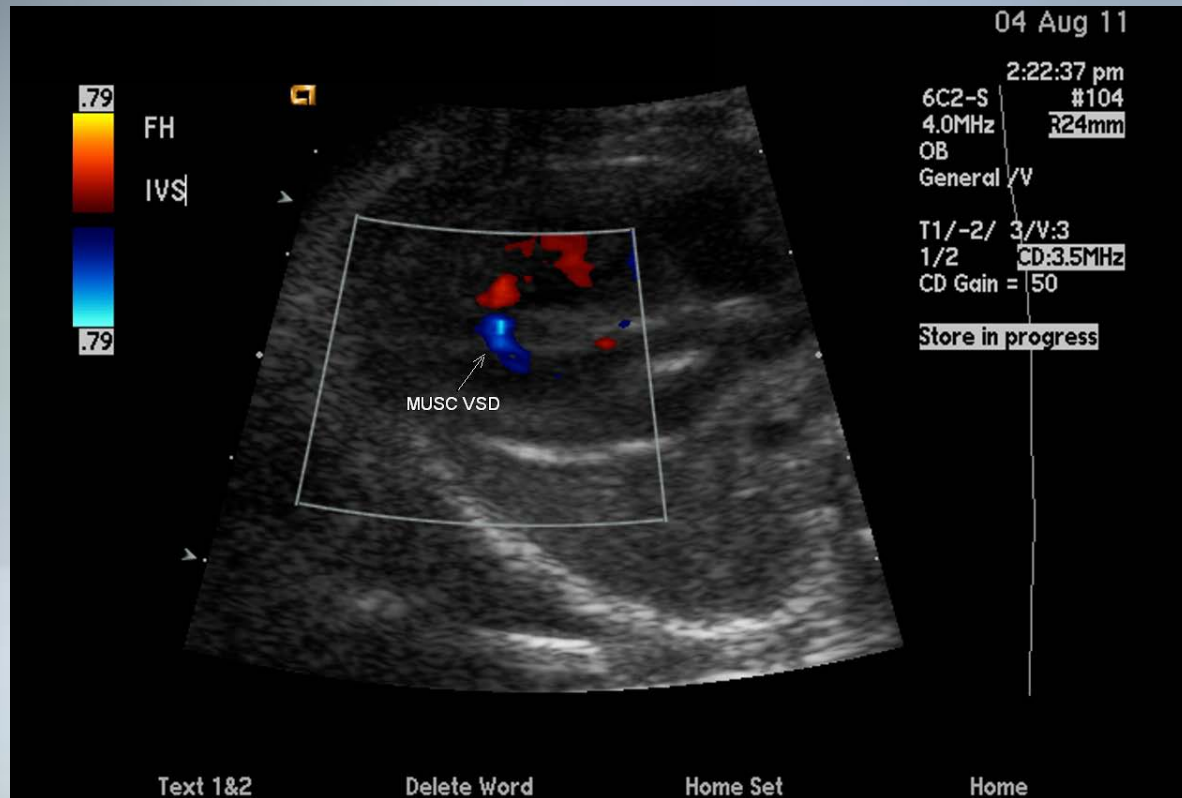




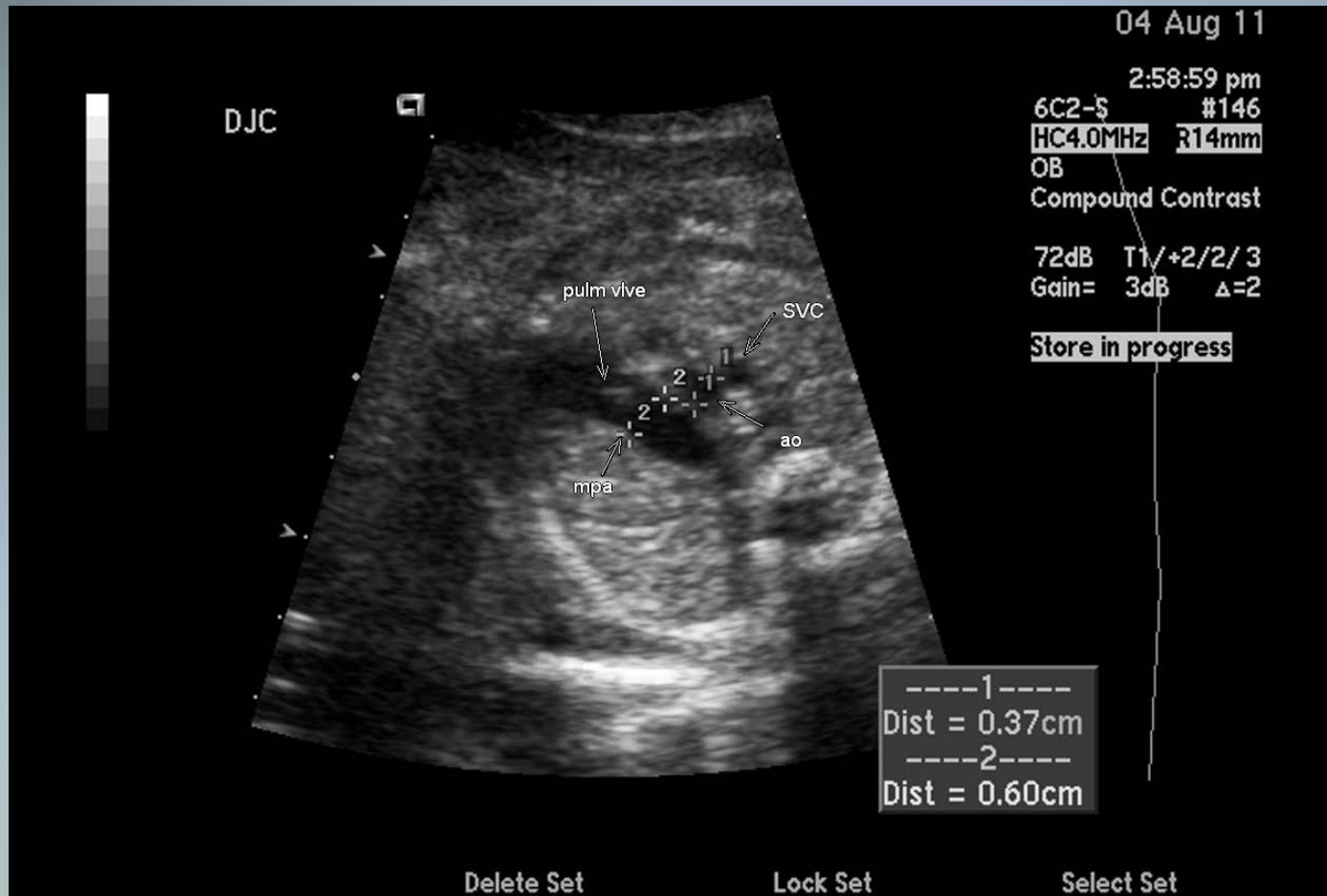
# Aortic coarctation – necessity of transverse imaging through upper chest



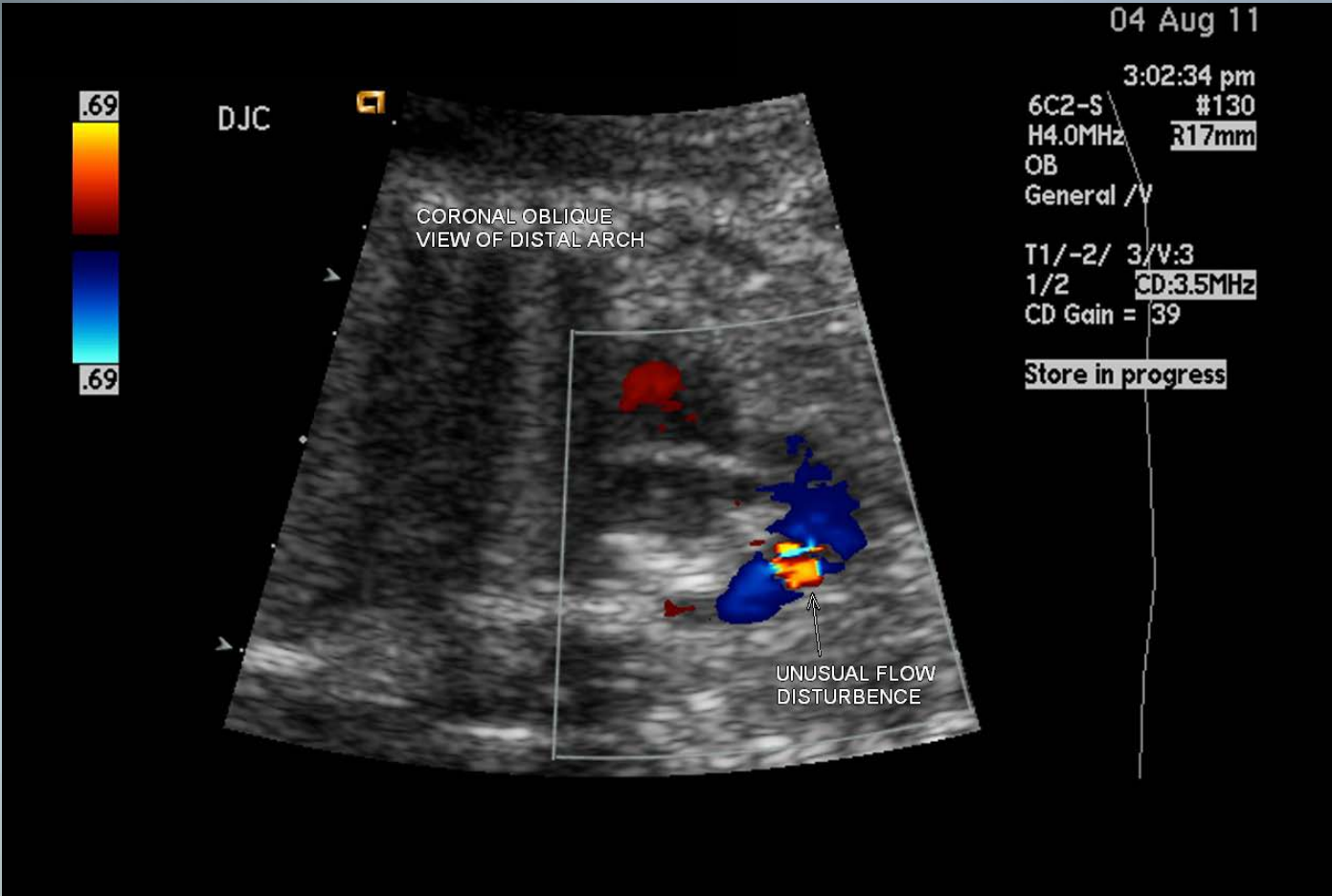
# Aortic coarctation – muscular VSD



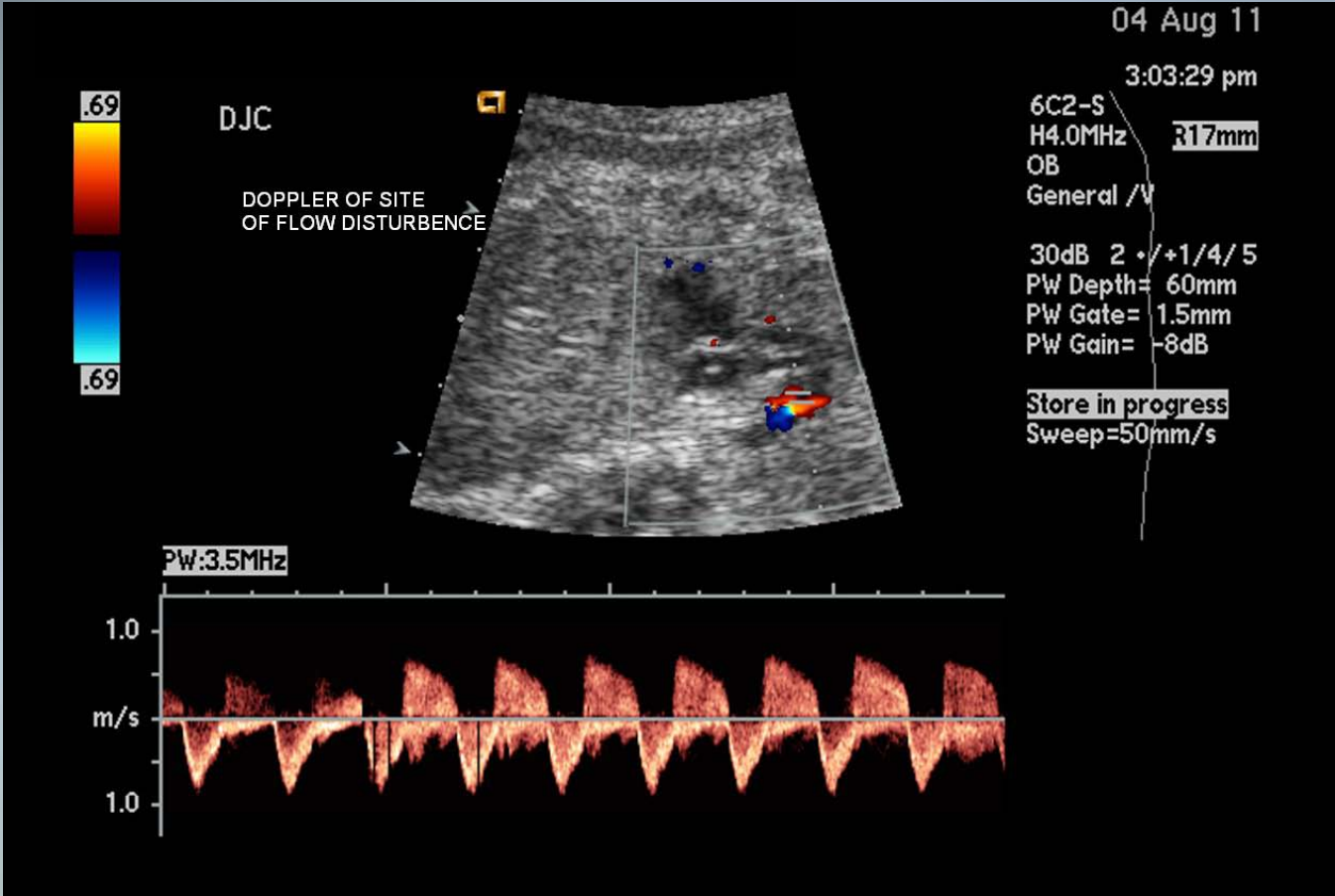
# Aortic coarctation – necessity of transverse imaging through upper chest



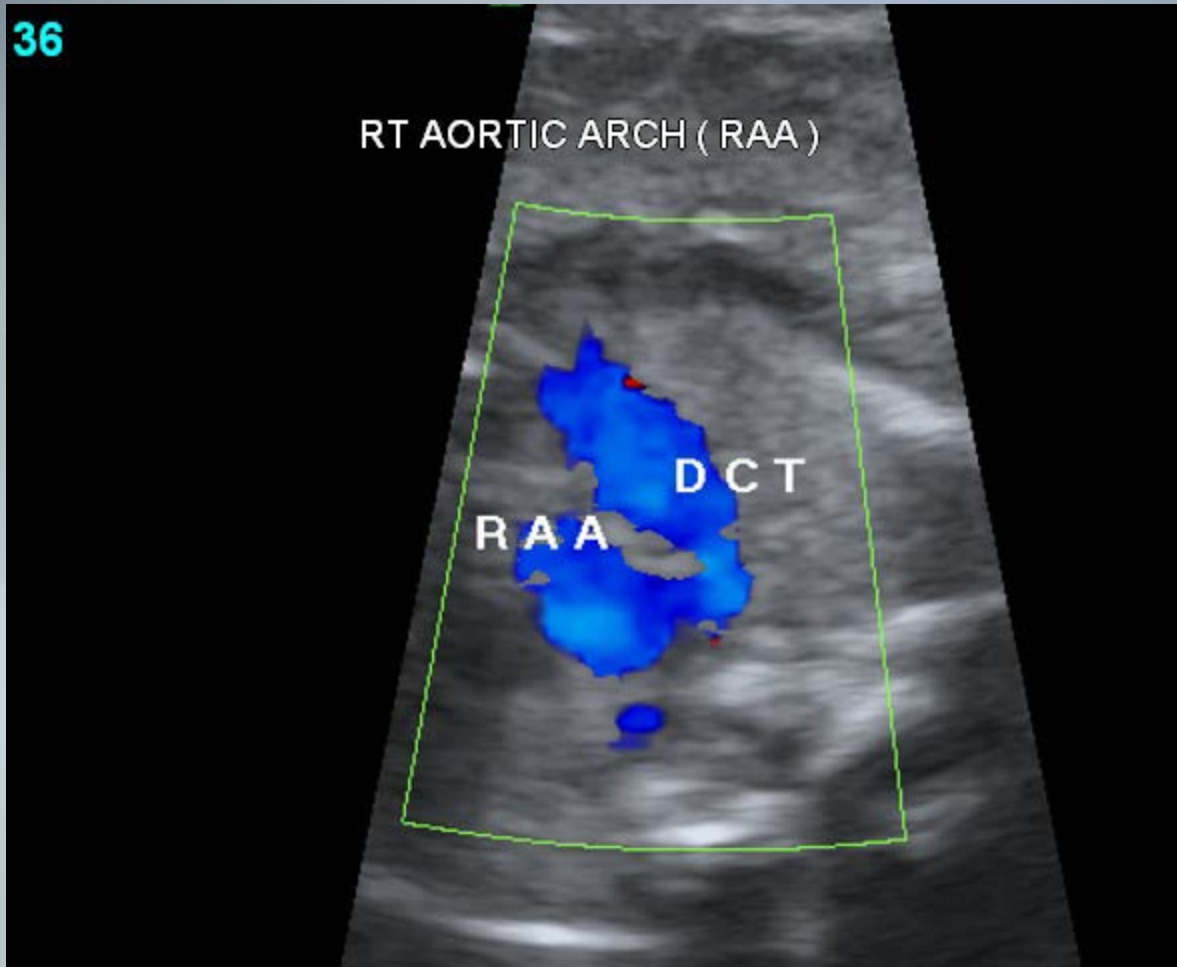
# Aortic coarctation – flow disturbance, critical stenosis



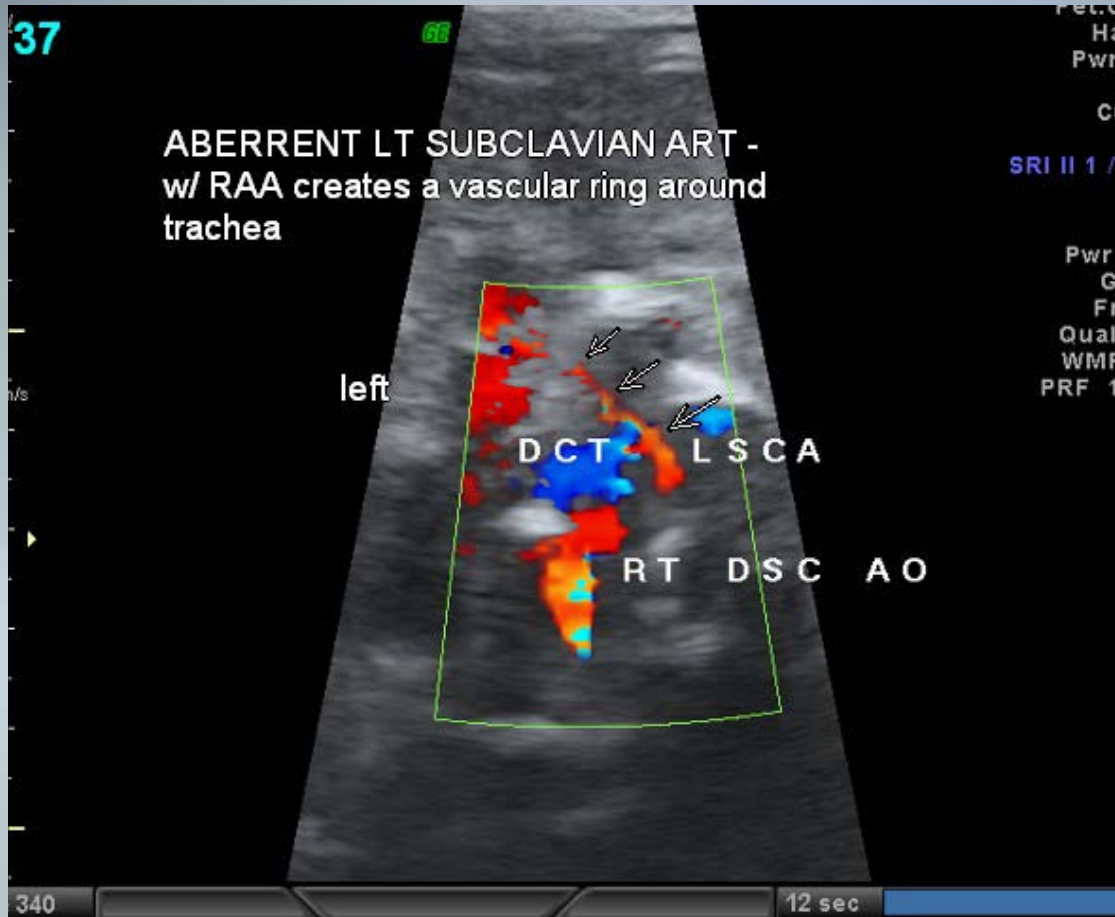
# Aortic coarctation - critical stenosis, reversal of diastolic flow



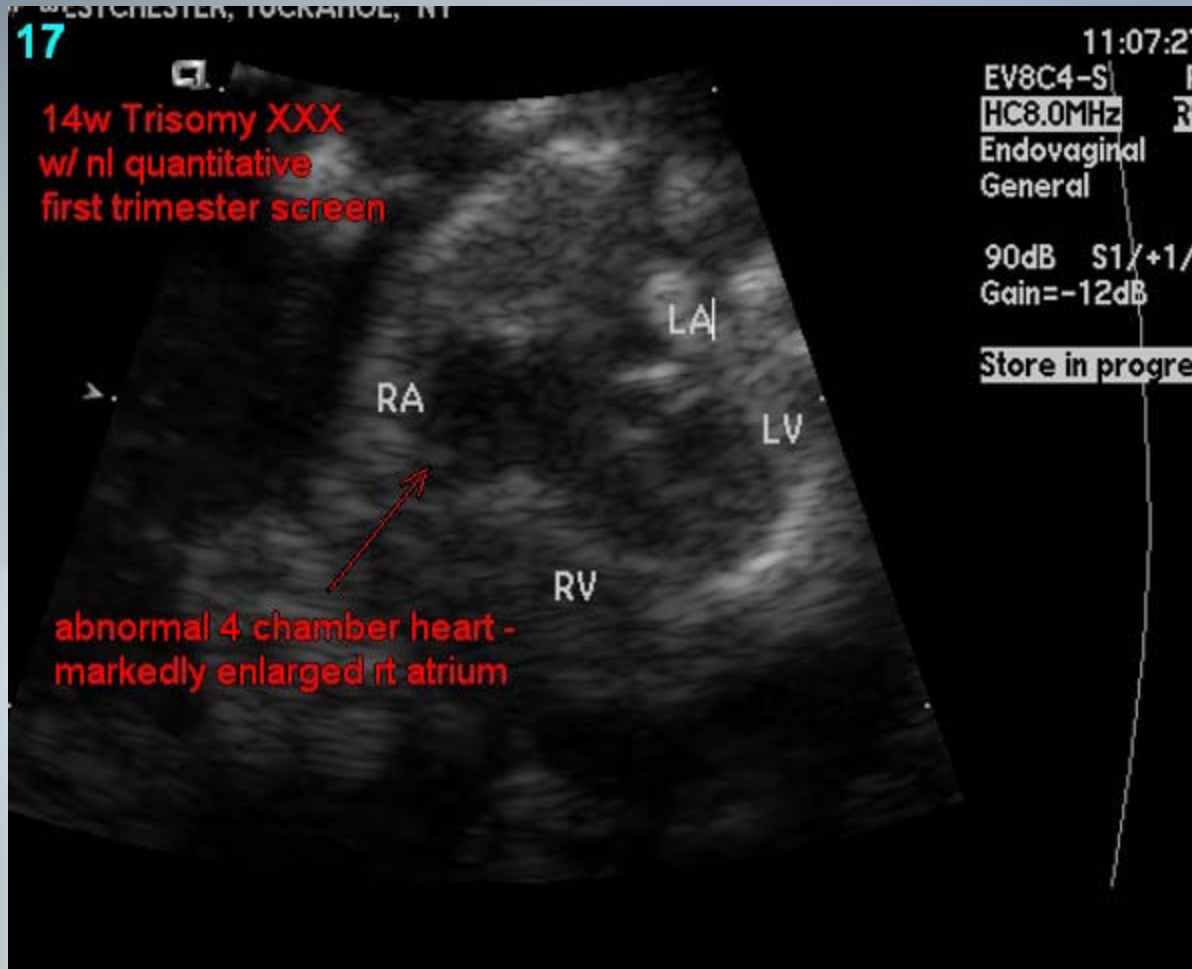
## Right aortic arch (RAA) – syndromic marker



# RAA with aberrant left subclavian artery – vascular ring, deliver at tertiary care center

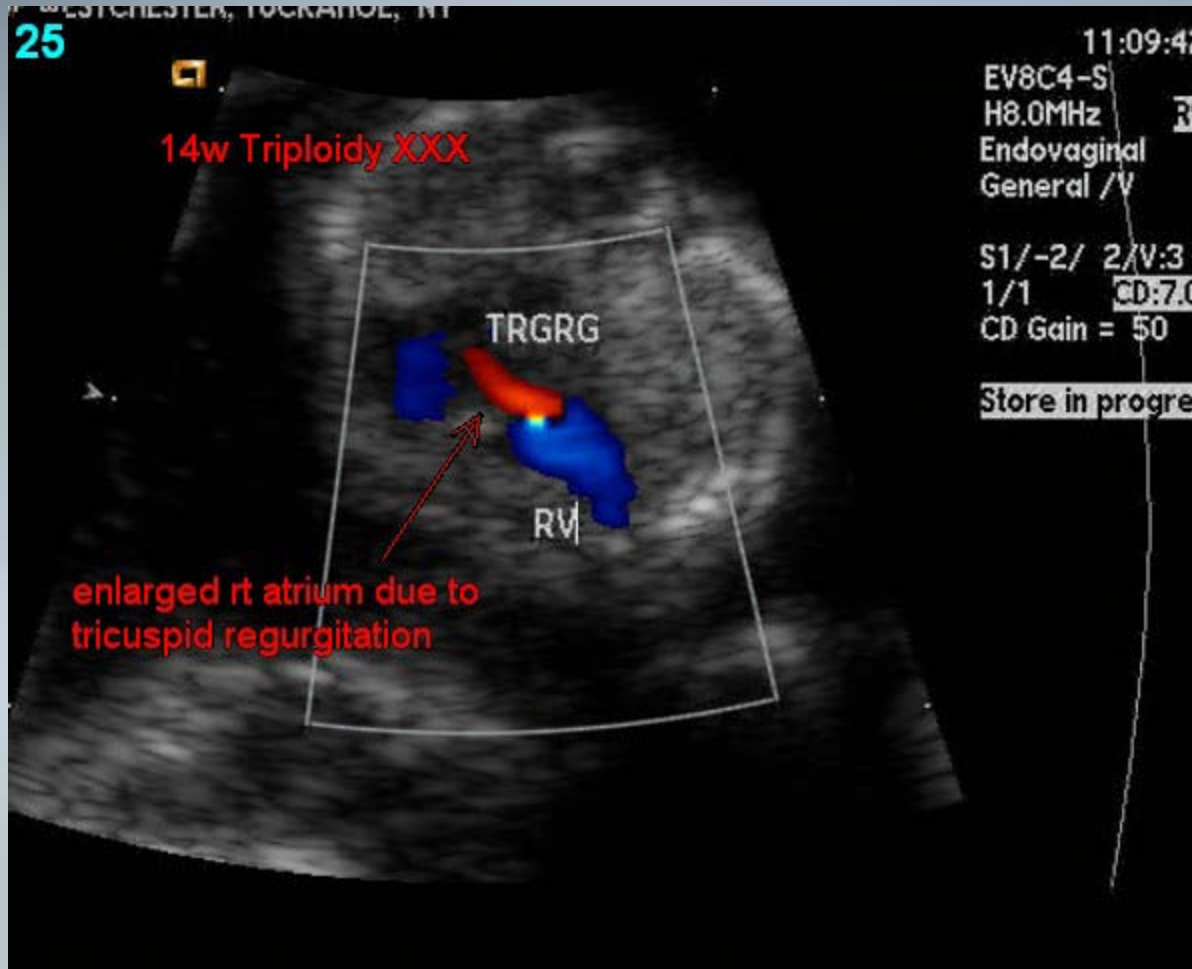


# 14-week triploidy XXX – enlarged right atrium

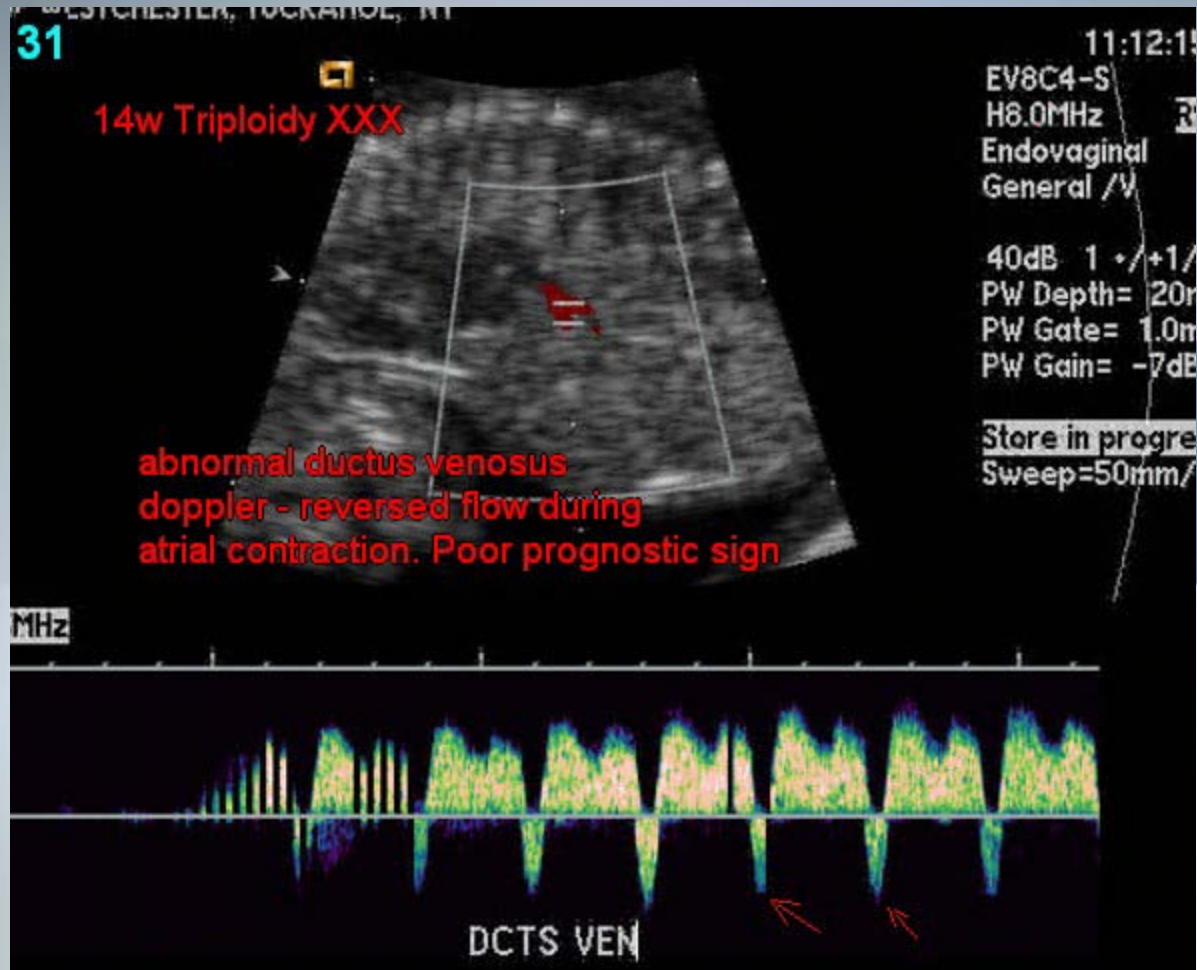




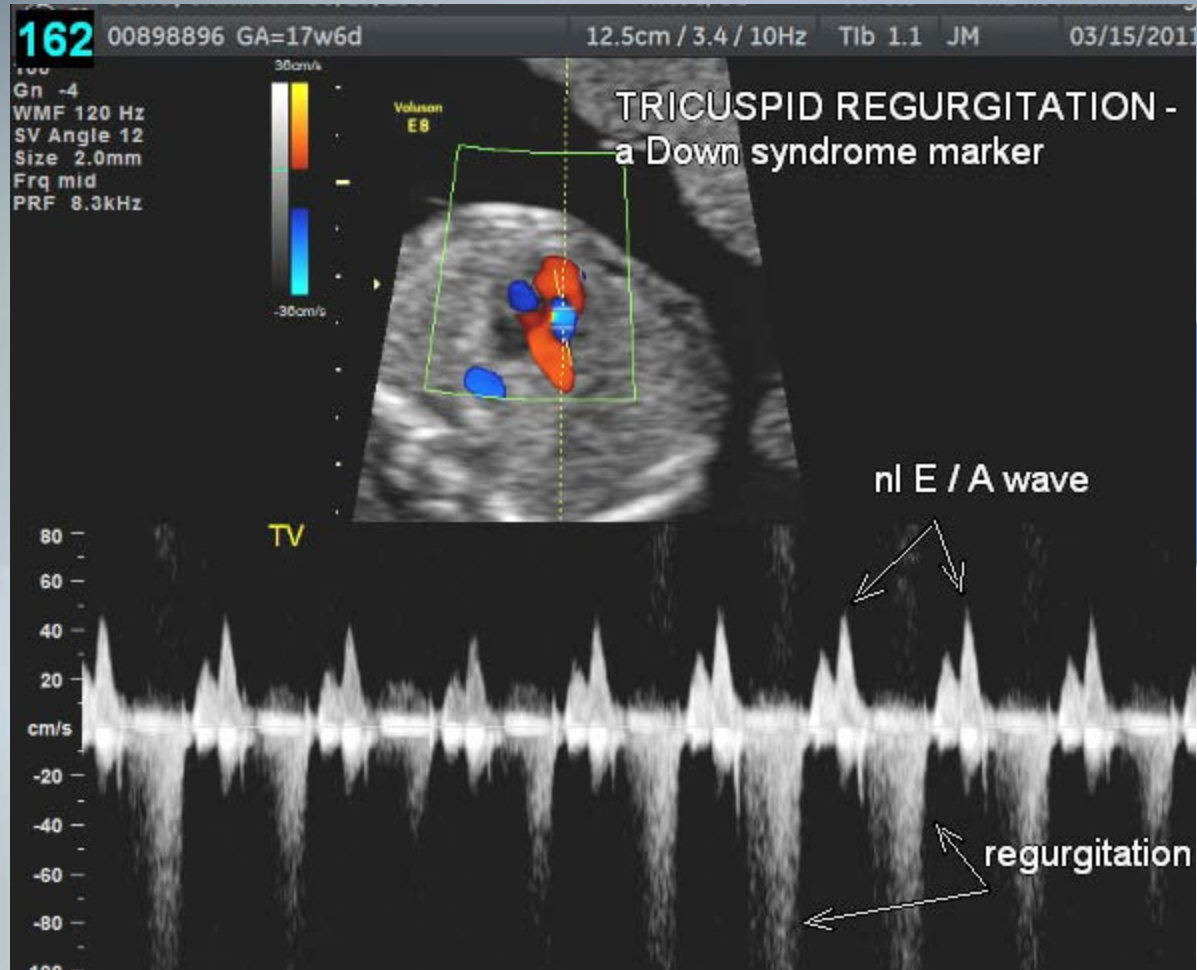
# 14-week triploidy XXX – tricuspid regurgitation



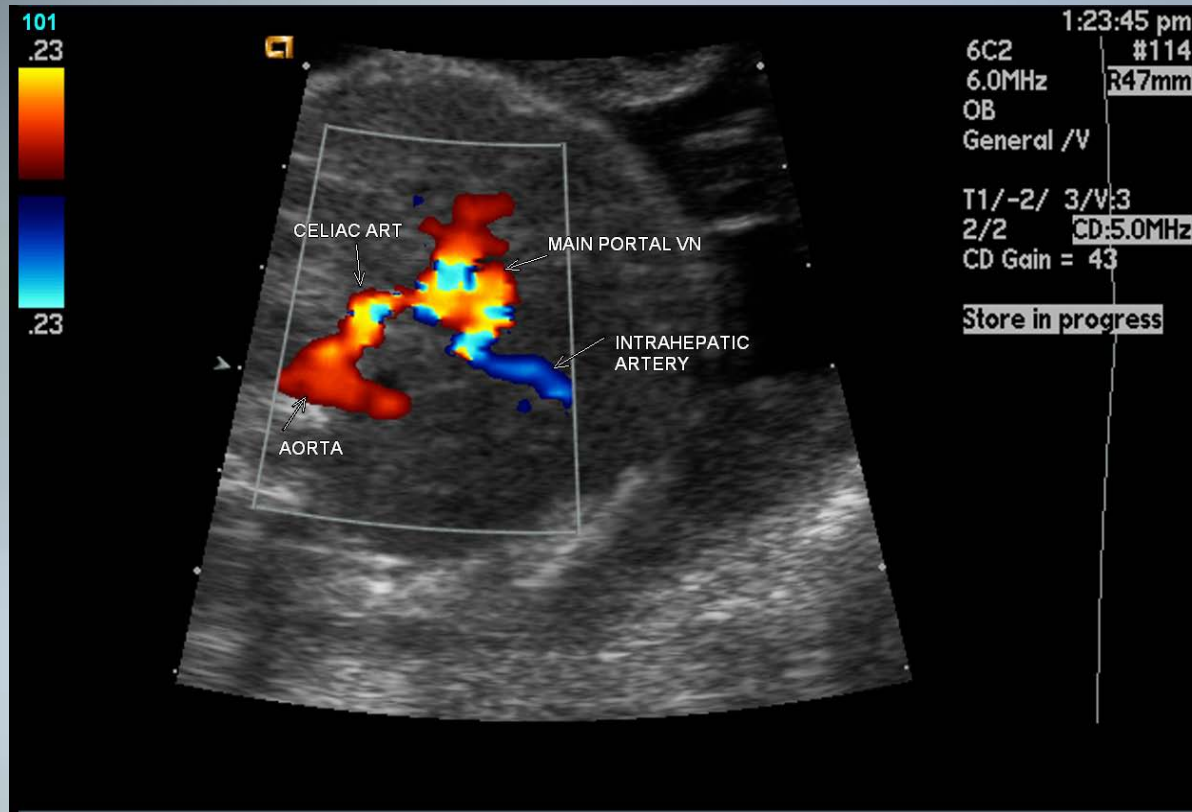
# 14-week triploidy XXX – abnormal ductus venosus



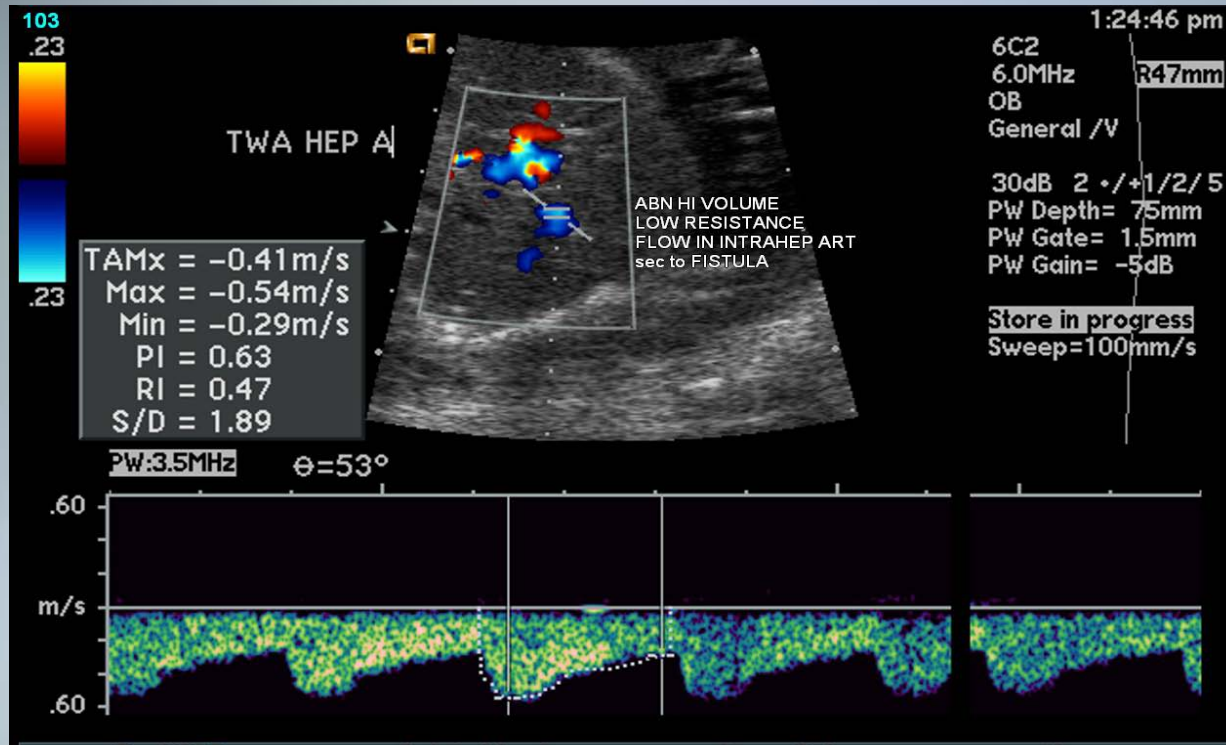
# Tricuspid regurgitation – Down syndrome marker



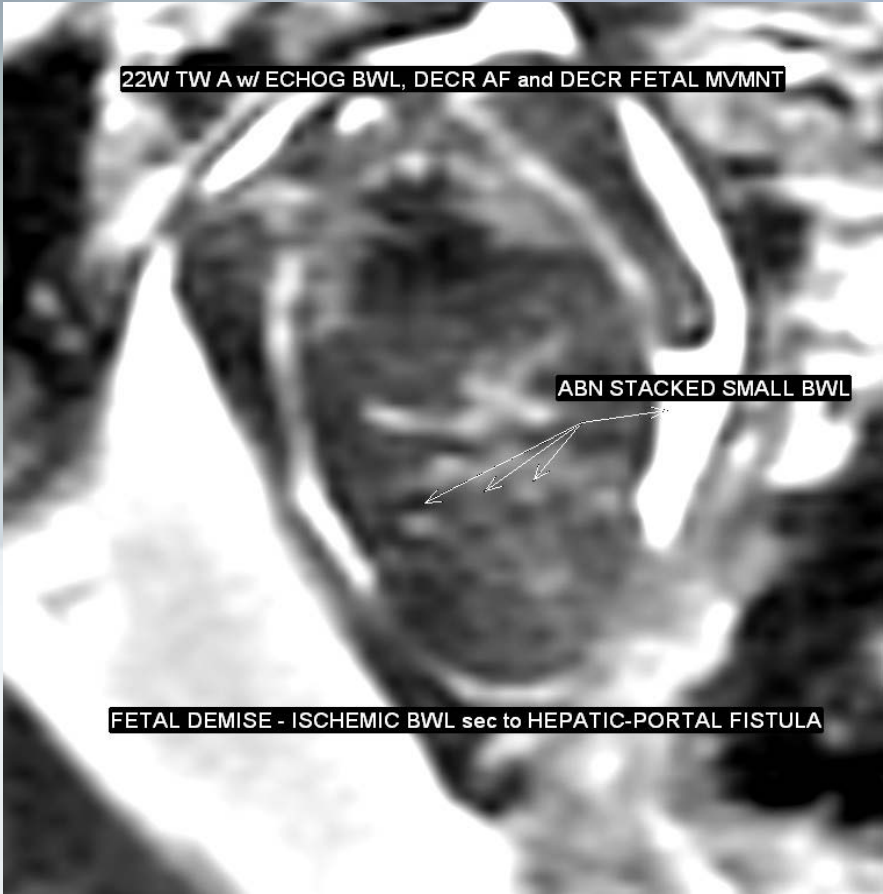# Fistula – celiac artery to portal vein. Fetal death two weeks later.



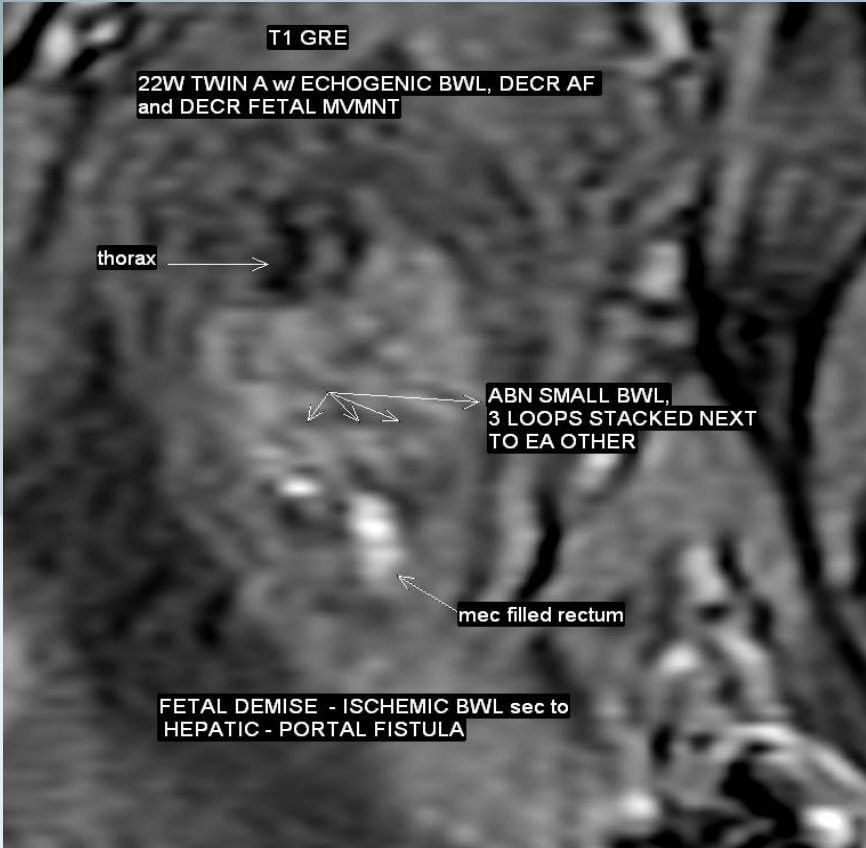
# Fistula – celiac artery to portal vein. Fetal death two weeks later.



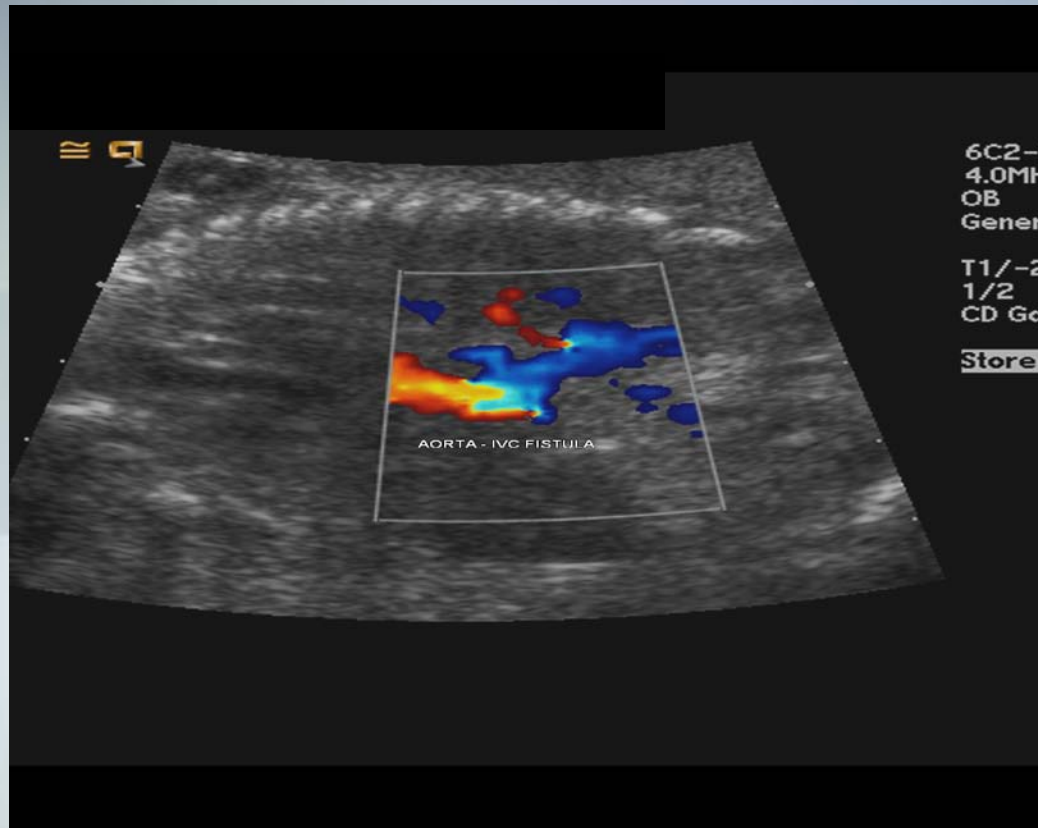
**Ischemic bowel secondary to A-V fistula. Fetal death.**



# Ischemic bowel secondary to A-V fistula. Fetal death.

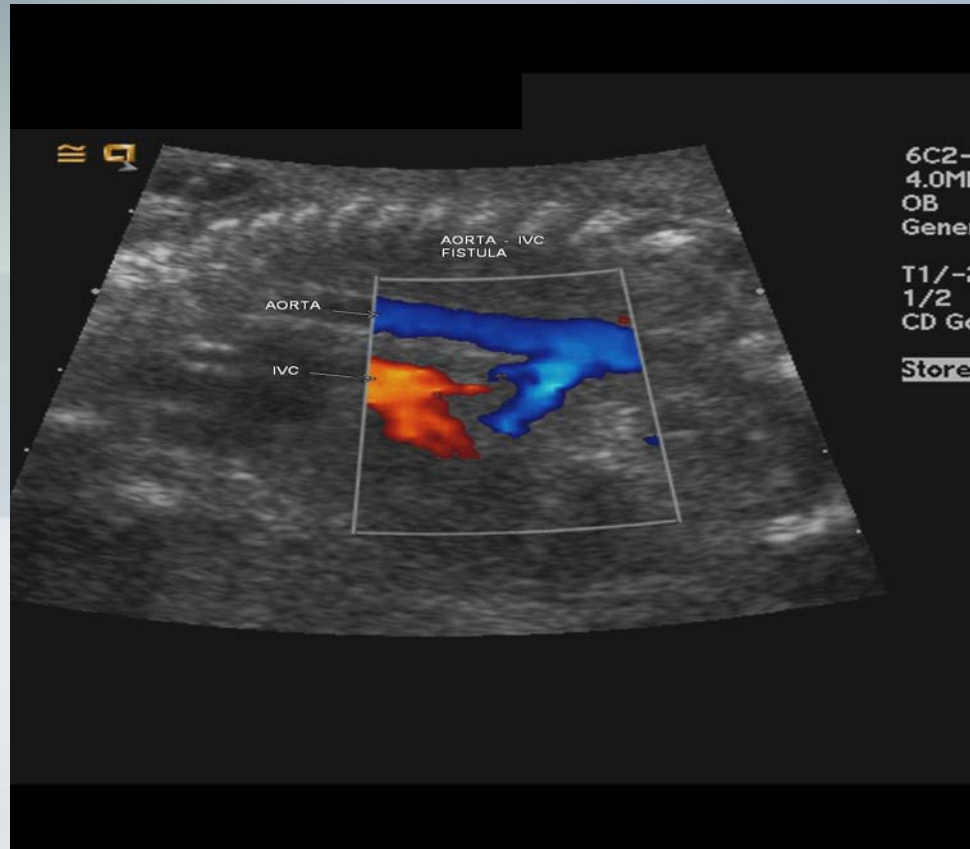


**Fistula – aorta to IVC. Severe IUGR. Cerebellar bleed.**

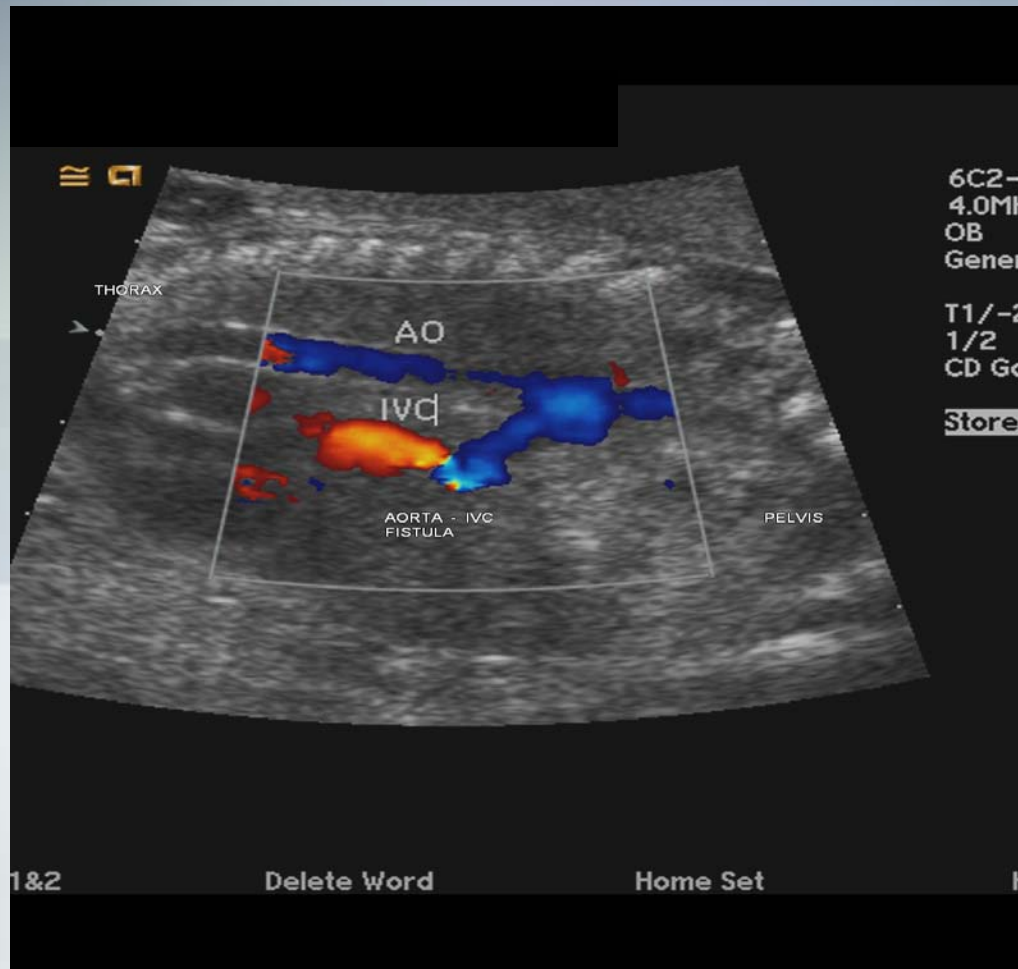




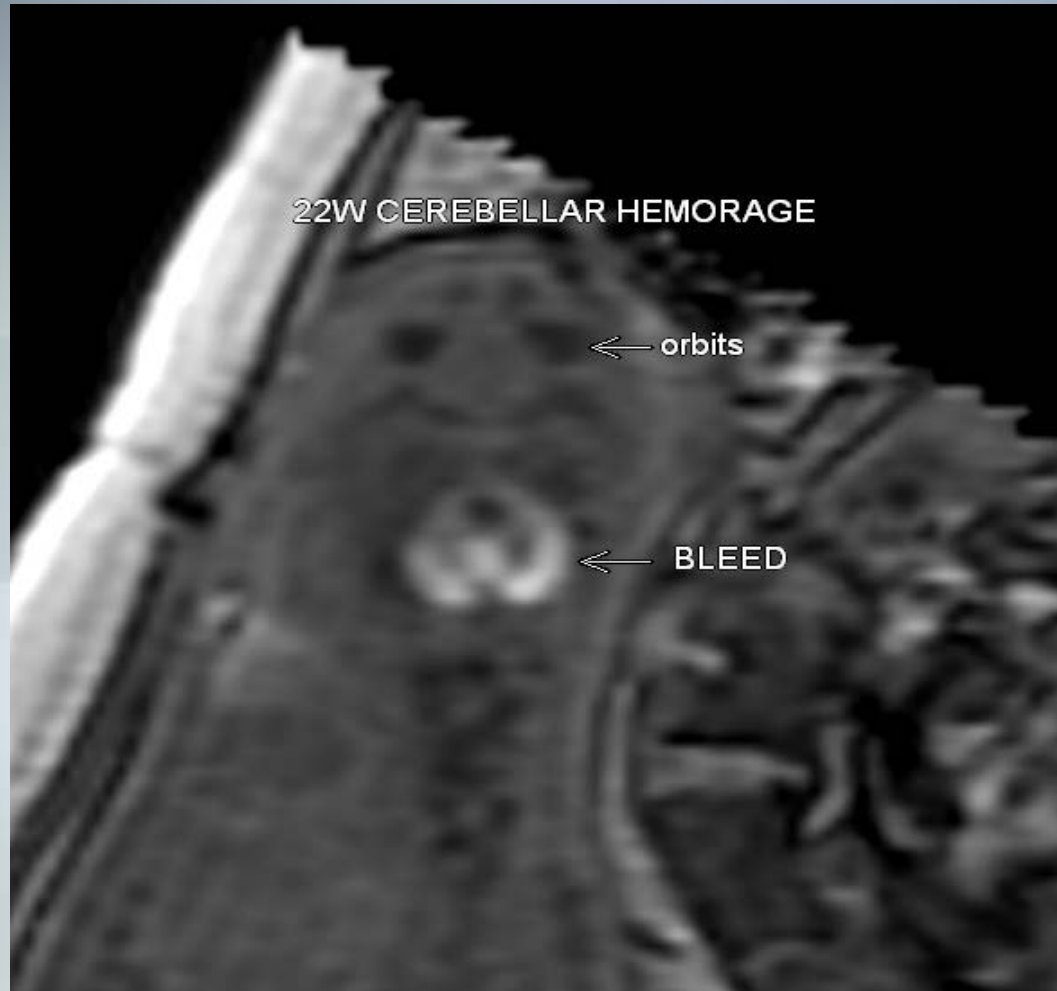**Fistula – aorta to IVC. Severe IUGR. Cerebellar bleed.**



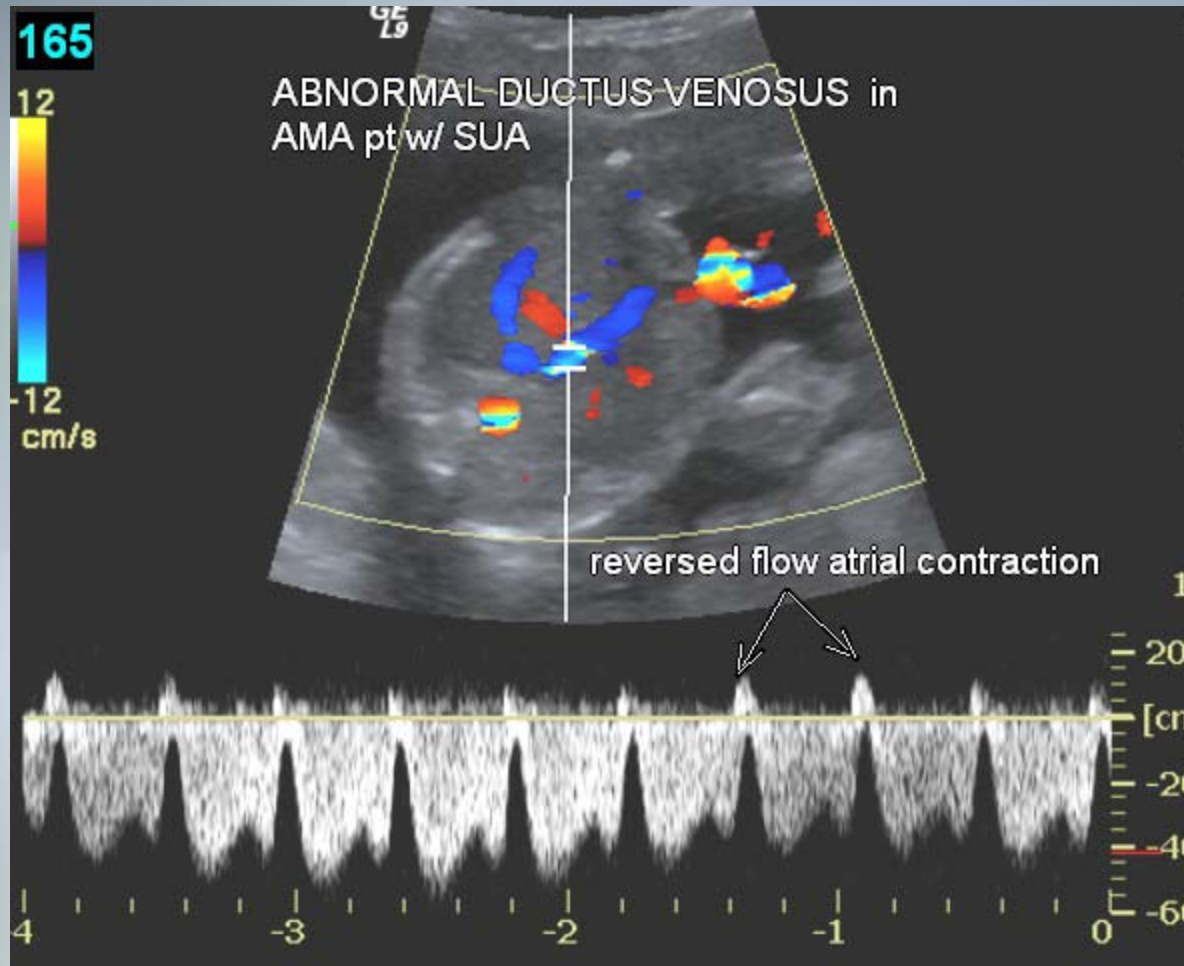
# Fistula – aorta to IVC. Severe IUGR. Cerebellar bleed.



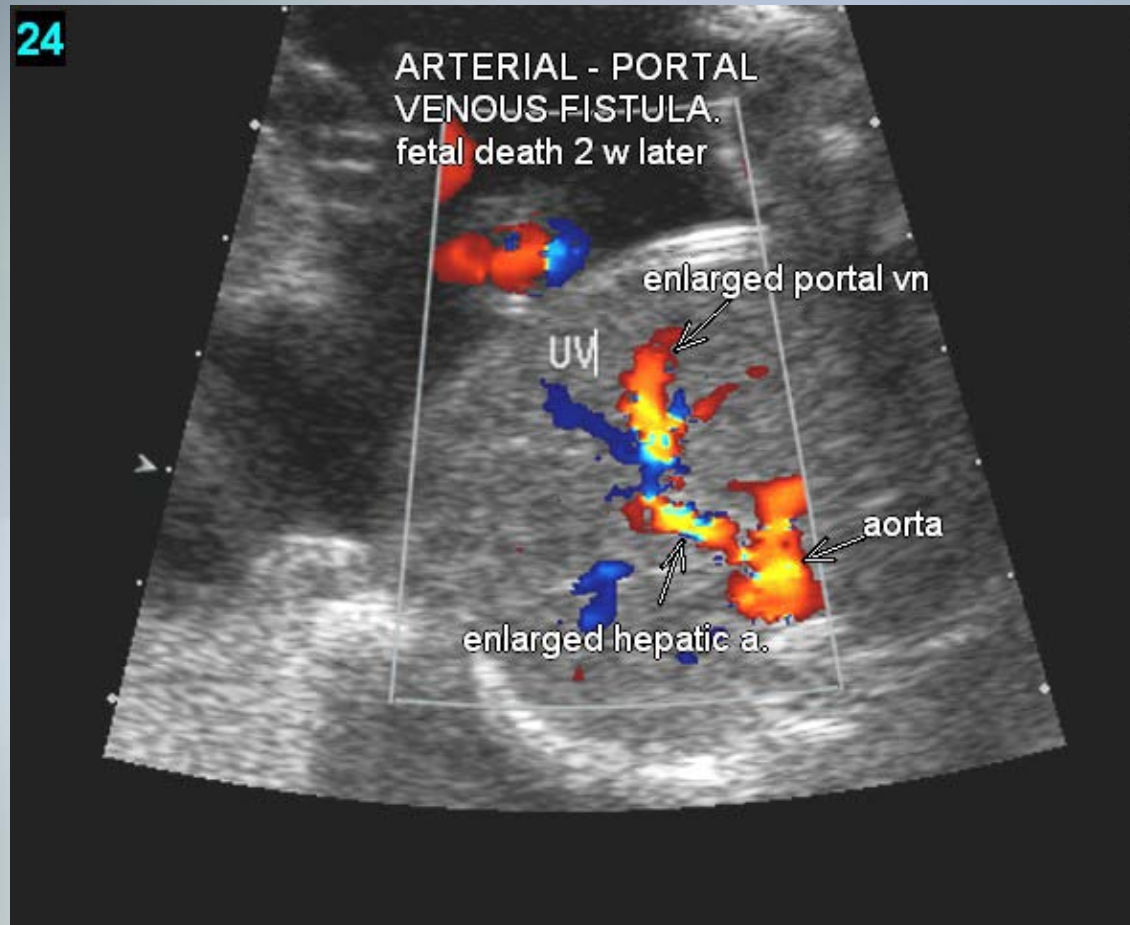
**Fistula – aorta to IVC. Severe IUGR. Cerebellar bleed.**



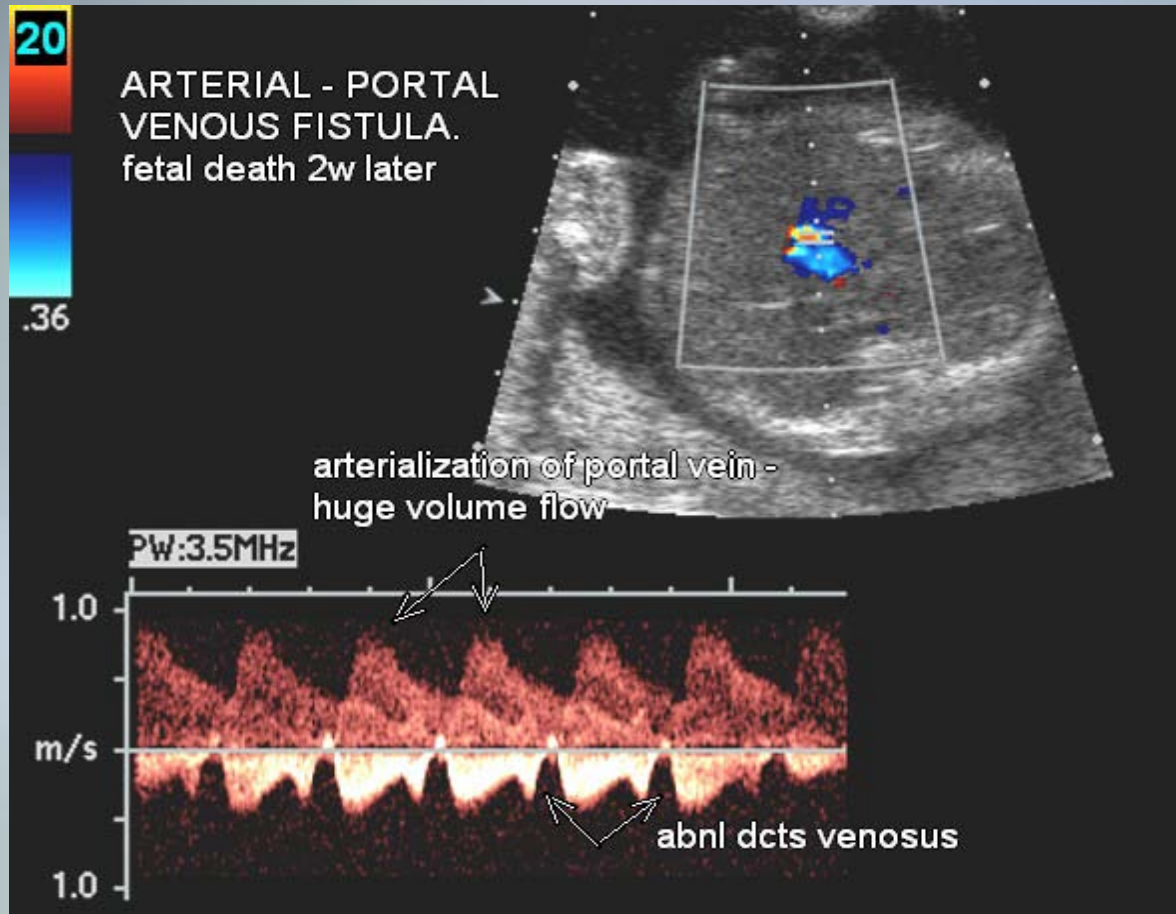
# Unscreened AMA with single umbilical artery. A-V fistula. Fetal death two weeks later



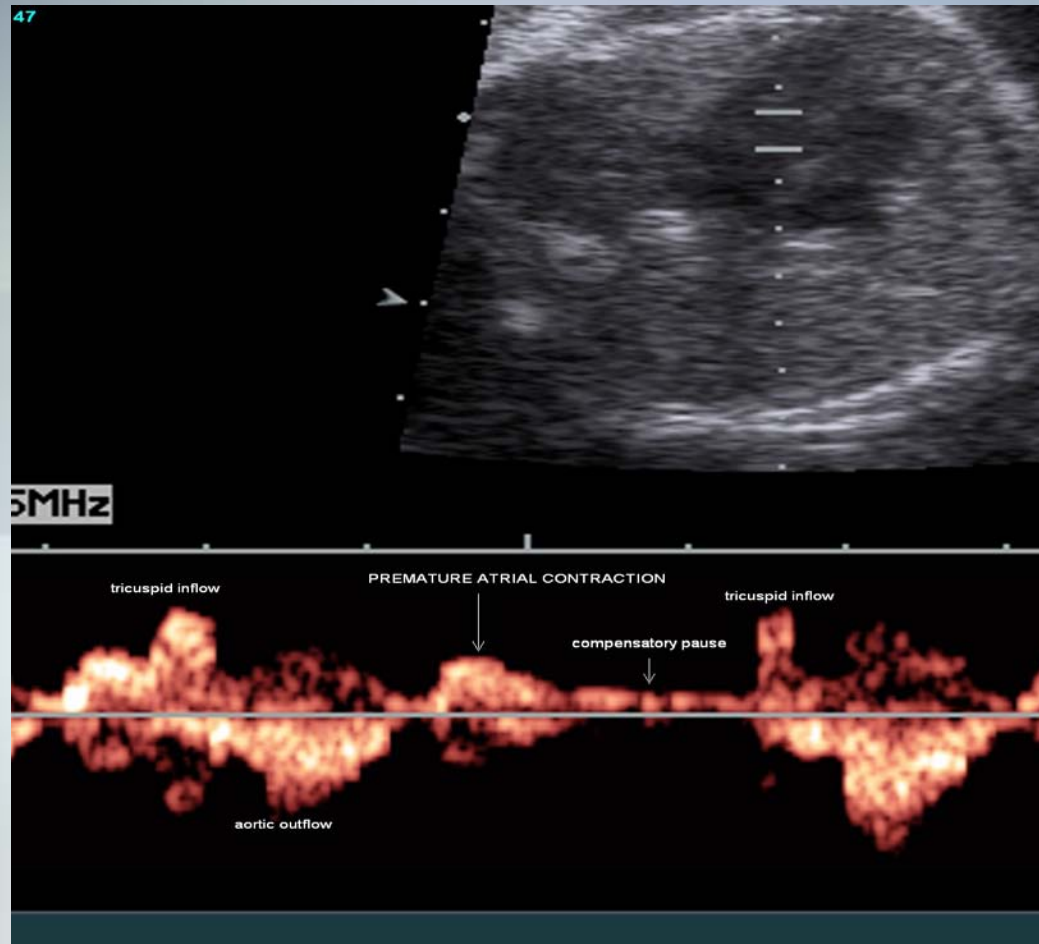
**Unscreened AMA with single umbilical artery. A-V fistula.  
Fetal death two weeks later**



# Unscreened AMA with single umbilical artery. A-V fistula. Fetal death two weeks later



# Audible dysrhythmia. Premature atrial contraction (PAC) with transient supraventricular tachycardiac (SVT)



## Transient SVT – atrial rate 266 bpm.

